

Surgical and Clinical Results of Extracranial Head and Neck Schwannomas: Analysis of 45 Patients

Ekstrakraniyal Baş Boyun Schwannomlarının Cerrahi ve Klinik Sonuçları: 45 Hastanın Analizi

^{ID} Mehmet Ekrem ZORLU^a, ^{ID} Mehmet Barış OKUMUŞ^a, ^{ID} Muammer Melih ŞAHİN^a,
^{ID} Metin Emin DEMİRKAN^a, ^{ID} Betül ÖĞÜT^b, ^{ID} Mehmet DÜZLÜ^a, ^{ID} Utku AYDİL^a

^aGazi University Faculty of Medicine, Department of Ear Nose and Throat Diseases, Ankara, Türkiye

^bGazi University Faculty of Medicine, Department of Pathology, Ankara, Türkiye

This study was presented as an oral at the 45th Turkish National Congress of Otolaryngology Head and Neck Surgery, October 23-27, 2024, TRNC

ABSTRACT Objective: The aim of this study was to retrospectively analyze the clinical and demographic characteristics, presenting symptoms, postoperative complications, nerve of origin, and location of schwannomas in patients operated for extracranial head and neck schwannomas. **Material and Methods:** Patients who underwent surgery for extracranial nonvestibular head and neck schwannomas between January 2008-August 2024 at the Gazi University Department of Ear Nose and Throat were included in the study. Clinical and demographic characteristics, presenting symptoms, tumor location and size, preoperative imaging and biopsy results, nerve of origin of the schwannoma, types of surgical procedures, postoperative complications, and follow-up findings were retrospectively analyzed. **Results:** The study included 45 patients. 14 (31.1%) of the patients were male and 31 (68.8%) were female, and the mean age was 39.08 years (9-82 years). The most common localization was the parapharyngeal region in 12 patients (26.6%). In 31 patients (68.9%), the nerve of origin could be identified before or during surgery. The nerve of origin was the vagus nerve in 11 patients (24.4%), facial nerve in 9 patients (20.4%), brachial plexus in 4 patients (8.8%), sympathetic trunk in 3 patients (6.6%), and cervical plexus in 2 patients (4.4%). Of the 40 patients in whom the tumor was excised, 17 (42.5%) had postoperative neurological deficit in the nerve of origin after surgery. **Conclusion:** Schwannomas are usually asymptomatic and slow-growing tumors but may lead to significant morbidity. Although surgery is the definitive treatment, there are different treatment options available considering asymptomatic patients. Patients should be informed that neurological deficits may occur after surgery.

ÖZET Amaç: Bu çalışmada, ekstrakraniyal baş boyun schwannomu nedeniyle opere edilen hastaların klinik ve demografik özellikleri, başvuru semptomları, operasyon sonrası komplikasyonları, schwannomun köken aldığı sinir ve yerleşim yerlerinin geriye dönük olarak analiz edilmesi amaçlanmıştır. **Gereç ve Yöntemler:** Gazi Üniversitesi Kulak Burun Boğaz Ana bilim Dalı'nda Ocak 2008-Ağustos 2024 yılları arasında ekstrakraniyal nonvestibüler baş ve boyun schwannomu nedeniyle opere edilen hastalar çalışmaya dâhil edildi. Hastaların klinik ve demografik özellikleri, başvuru semptomları, tümör lokasyon ve boyutları, operasyon öncesi görüntüleme ve biyopsi sonuçları, schwannomun köken aldığı sinir, cerrahi prosedür tipleri, postoperatif komplikasyonlar ve takip bulguları retrospektif olarak analiz edildi. **Bulgular:** Çalışmaya 45 hasta dâhil edildi. Hastaların 14'ü (%31,1) erkek, 31'i (%68,8) kadın olup ortalama yaş 39,08 (9-82 yaş) olarak saptandı. En sık yerleşim yeri olarak 12 hastada (%26,6) parafarengeal bölge tespit edildi. 31 hastada (%68,8) tümörün köken aldığı sinir cerrahi öncesinde veya operasyon sırasında belirlenebildi. Kitlenin kaynaklandığı sinir 11 hastada (%24,4) 10. kraniyal sinir, 9 hastada (%20,4) 7. kraniyal sinir, 4 hastada (%8,8) brakial pleksus, 3 hastada (%6,6) servikal sempatik zincir, 2 hastada (%4,4) hastada servikal pleksus kökenli olarak izlendi. Tümörün eksize edildiği 40 hastanın 17'sinde (%42,5) cerrahi sonrası ilgili sinirde nörolojik defisit saptandı. **Sonuç:** Schwannomların çoğunlukla asemptomatik ve yavaş büyüyen tümörler olmalarına rağmen önemli morbiditelere sebep olabilirler. Cerrahi kesin tedavi olmakla birlikte asemptomatik hastalar da göz önünde bulundurulduğunda farklı tedavi seçenekleri bulunmaktadır. Cerrahi sonrası nörolojik defisitlerin gelişebileceği hastayla paylaşılmalıdır.

Keywords: Cranial nerves; head and neck tumors; schwannomas

Anahtar Kelimeler: Kraniyal sinirler; baş boyun tümörleri; schwannomalar

TO CITE THIS ARTICLE:

Zorlu ME, Okumuş MB, Şahin MM, Demirkan ME, Ögüt B, Düzlülü M, Aydın U. Surgical and Clinical Results of Extracranial Head and Neck Schwannomas: Analysis of 45 Patients. Journal of Ear Nose Throat and Head Neck Surgery. 2025;33(3):106-14.

Correspondence: Mehmet Ekrem ZORLU

Gazi University Faculty of Medicine, Department of Ear Nose and Throat Diseases, Ankara, Türkiye

E-mail: m_ekrem_zorlu@hotmail.com



Peer review under responsibility of Journal of Ear Nose Throat and Head Neck Surgery.

Received: 04 Mar 2025

Accepted: 07 Apr 2025

Available online: 29 Apr 2025

1307-7384 / Journal of Ear Nose Throat and Head Neck Surgery is the official publication of the Ear Nose Throat and Head Neck Surgery Society. Production and hosting by Türkiye Klinikleri. This is an open access article under the CC BY-NC-ND license (<https://creativecommons.org/licenses/by-nc-nd/4.0/>).

Schwannomas are benign, encapsulated nerve sheath neoplasms originating from Schwann cells. Although it can be observed in individuals of all age groups, it is most common among those between the ages of 20 and 50 years.¹ Men and women are equally affected and about 25% to 45% are found in the head and neck region.²

They are found in many different regions, including the oral cavity, nasal cavity, parapharyngeal space, and middle ear.² The clinical presentation of schwannomas may vary depending on the nerve of origin or the site of localization.³ Although these tumors are typically asymptomatic and slow growing, they may cause morbidity due to the compression of the surrounding tissues. There is no consensus on the treatment, and there are different opinions ranging from close follow-up to intracapsular enucleation and complete excision of the mass depending on the nerve from which the mass originates.⁴⁻⁶

In this study, we aimed to present the diagnosis, treatment, and surgical resection results of 45 patients who were followed up and treated for extracranial head and neck schwannomas in our clinic with the current literature.

MATERIAL AND METHODS

This study included 45 patients who underwent surgery for extracranial nonvestibular head and neck schwannomas at the Gazi University Department of Ear Nose and Throat between January 2008-August 2024. Patients with schwannomas not located in the head and neck region, located intracranially and originating from the vestibular nerve were not included in the study. Patients who were not followed up regularly were not included in the study. Patients who were followed up for schwannoma without surgery or who received other treatment modalities as primary treatment, such as radiation therapy, were also not included in the study. One patient who underwent surgery for a malignant peripheral nerve sheath tumor or malignant schwannoma was excluded from the study. This study followed the tenets of the Declaration of Helsinki criteria and was approved by the Gazi University Ethics Commission with the July 30, 2024

dated and 13 numbered meeting. Informed consent was obtained from all patients.

Clinical and demographic characteristics, presenting symptoms, tumor location and size, preoperative imaging and fine needle aspiration biopsy (FNAB) results, nerve of origin, types of surgical procedures, and postoperative complications were retrospectively analyzed. Furthermore, patients were contacted and asked whether they had been experiencing any ongoing symptoms.

Facial nerve monitoring was used for schwannomas originating from the facial nerve, vagal-recurrent nerve monitoring was used for parapharyngeal masses, and intraoperative monitoring of the brachial plexus was performed for masses originating from the brachial plexus.

Statistical analysis was performed with IBM SPSS version 22 (IBM, Armonk, NY, USA). The results were presented as numbers (n), percentages, means, and minimum-maximum.

RESULTS

A total of 45 cases of head and neck schwannomas were retrospectively analyzed. All of patients' diagnosis was confirmed at the department of pathology except for 3 asymptomatic patients who underwent surgery without excising the tumor (Figure 1). Of the patients, 14 (31.1%) were male and 31 (68.8%) were female with a mean age of 39.08 years (9-82 years). The presenting signs and symptoms are summarized in Table 1. The most common presenting complaint was painless swelling in the neck in 26 patients (57.7%), and the most common location of the mass was the parapharyngeal region in 12 patients (26.6%). The localization of the schwannomas is shown in Table 2. The accompanying symptoms varied according to the location of the tumor.

Ultrasonography (USG), Computed Tomography (CT), and magnetic resonance imaging (MRI) were used as preoperative imaging techniques. Preoperative imaging was performed in all patients except for 3 patients with superficial tumors located under the scalp in the postauricular region, on the right half of the tongue and under the skin in the midline of the neck. CT was performed in 10 patients,

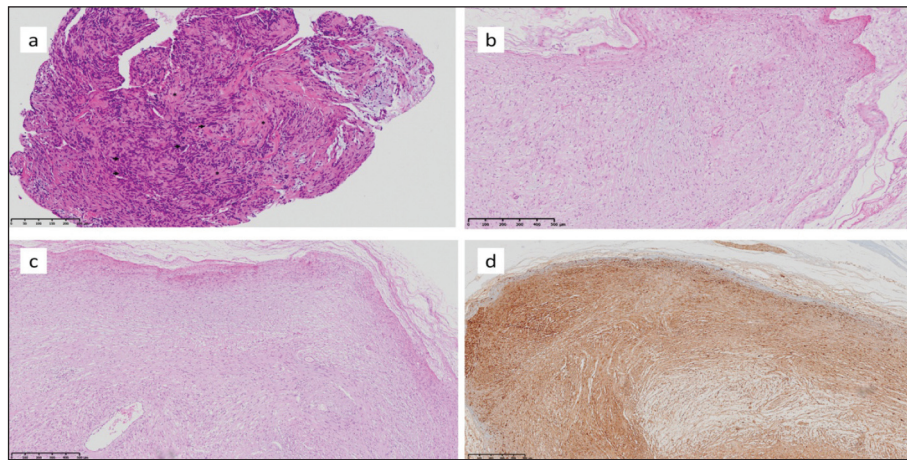


FIGURE 1: a) A subtotally excised Schwannoma case with a spindle cell appearance and indistinct borders. The identification of Antoni B (showed with "**") and hypercellular Antoni A areas (showed with " ") raises suspicion for Schwannoma (H&E) x85. b, c) A well-circumscribed spindle cell tumor (H&E) x50 x50. d) Immunohistochemically, the tumor expressed S-100 protein x50.

TABLE 1: Presenting signs and symptoms of the patients

Neck swelling	24 (56.8%)
Swelling on the cheek or scalp	4 (9.0%)
Insidental	6 (9.0%)
Facial paralysis	4 (9.0%)
Conductive type hearing loss	3 (6.8%)
Swelling in the oral cavity	3 (6.8%)
Facial numbness	1 (2.2%)
Nasal obstruction	2 (4.5%)
Headache	1 (2.2%)

TABLE 2: Anatomical sites of extracranial head and neck schwannomas

Parapharyngeal space	12 (26.6%)
Neck	9 (20%)
Supraclavicular fossa	5 (11.1%)
Parotid gland	5 (11.1%)
Middle ear	4 (8.8%)
Sinonasal cavity	4 (8.8%)
Oral cavity	2 (4.4%)
Infratemporal fossa	1 (2.2%)
Scalp	1 (2.2%)
Hypopharynx	1 (2.2%)
Larynx	1 (2.2%)
Total number	45 (100%)

MRI in 36 patients and USG in 21 patients. In 17 patients MRI and USG, in 1 patient CT and USG, in 5

patients CT and MRI were used together. In 3 patients, CT, MRI, and USG were used in combination. The mean schwannoma size was 33.7 mm (minimum; 6 mm, maximum; 110 mm).

FNAB was performed on 21 patients before surgery. In 9 of these patients (42.8%), the FNAB result was reported as schwannoma. 8 FNAB samples were determined to be nondiagnostic, 2 samples were identified as suspicious for malignancy, 1 sample was diagnosed as paraganglioma, and 1 sample was identified as fibroadipose tissue with chronic inflammation.

In 31 patients (68.9%), the nerve of tumor origin was identified before or during surgery (Table 3). The nerve of origin was the 10th cranial nerve in 11 patients (24.4%), 7th cranial nerve in 9 patients (20.4%), brachial plexus in 4 patients (8.8%), sympathetic trunk in 3 patients (6.6%), cervical plexus in 2 patients (4.4%), vidian nerve in 1 patient (2.2%), and 5th cranial nerve in 1 patient (2.2%). Figure 2a, Figure 2b, and Figure 2c show a schwannoma of sympathetic trunk origin located in the carotid bifurcation.

In 37 patients (82.2%), the tumor was completely excised. The tumor was subtotally excised in 3 patients (6.6%): one patient with a mass located in the posterior wall of the maxillary sinus and sphenoid sinus, one patient with a mass located in the tympanic

TABLE 3: The nerve of origin of schwannomas

Vagus nerve	11 (24.4%)
Facial nerve	9 (20.4%)
Brachial plexus	4 (8.8%)
Sympathetic trunk	3 (6.6%)
Cervical plexus	2 (4.4%)
Vidian nerve	1 (2.2%)
Trigeminal nerve	1 (2.2%)
Nerve could not be identified	14 (31.1%)

cavity, and one patient with a mass located in the right infratemporal and pterygopalatine fossa. In one patient with facial nerve schwannoma and one patient with maxillary sinus schwannoma, intraoperative biopsy was performed, and the operation was terminated. In the patient with facial nerve schwannoma, the frozen section result was a malignant mesenchymal tumor, while the definitive pathology result was a schwannoma. There has been no growth in the residual mass after treatment with stereotactic radiosurgery within 13 years. In 3 asymptomatic patients

(6.8%) with 7th cranial nerve, 10th cranial nerve and brachial plexus origin, the relationship of the tumor with the nerve of origin was seen intraoperatively (Figure 3). The operation was terminated without excising the tumor, and follow-up was decided after consultation with the patients.

Surgical approaches were planned considering the location and size of the tumor. Tumors located in the neck were excised using the transcervical approach, whereas tumors located in the nasal and paranasal cavity were removed by functional endoscopic sinus surgery. The transcervical and transparotid approach was performed in a patient with a parapharyngeal mass. A transoral approach was used for tumors located in the oral cavity, in a patient with a mass in the posterior hypopharynx, and in a patient with a mass in the supraglottic region. Intracapsular enucleation was performed in one patient with schwannoma originating from the brachial plexus and in 3 patients with vagal schwannomas. In the postoperative follow-up of patients who underwent intracapsular enucleation, one patient with

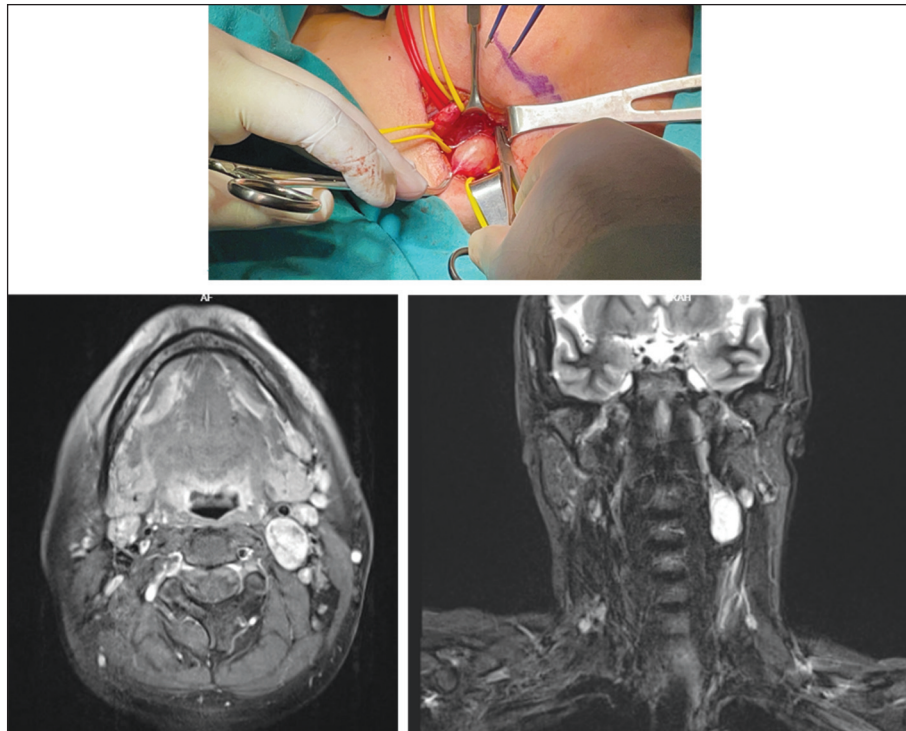


FIGURE 2: 2a: Intraoperative view of a 22x16 mm schwannoma arising from the sympathetic trunk. 2b: Contrast enhanced axial T1-weighted MRI image of the schwannoma located in the carotid bifurcation of the same patient. 2c: Contrast enhanced coronal T2-weighted MRI image of the patient

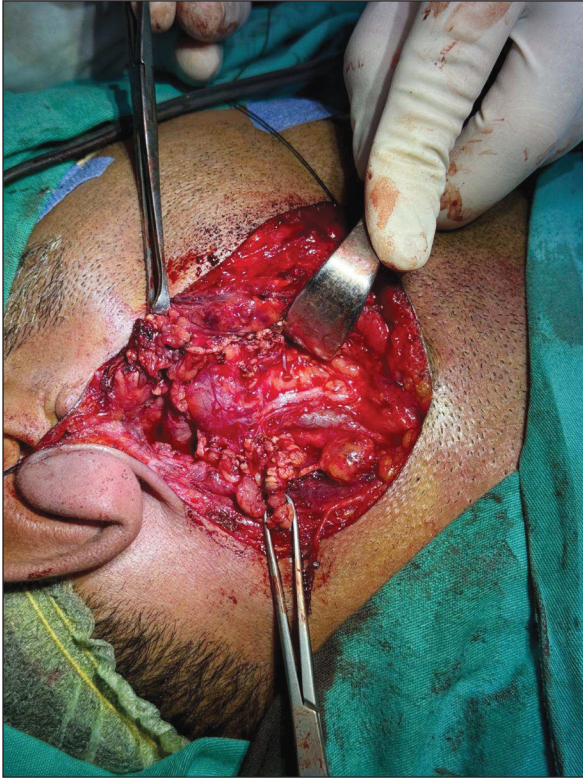

FIGURE 3: The appearance of a schwannoma of facial nerve origin

vagal schwannoma had postoperative vocal cord paralysis and was treated with type 1 thyroplasty. The patient with a mass originating from the brachial plexus had mild postoperative weakness (4/5), which improved after physical therapy.

The mean follow-up period of the patients included in the study was 71.6 months (3-165 months). Recurrence occurred in one patient during the follow-up period. Subtotal excision was performed in a patient with a 60 mm schwannoma located in the infratemporal fossa and extending into the cavernous sinus. After 8 years, due to the growth of the residual tumor, subtotal excision was performed via endoscopic intranasal surgery, and the patient received postoperative stereotactic radiosurgery. The residual tumor did not grow during follow-up. A patient with a 5 cm mass located at the left carotid bifurcation and a paraganglioma as a result of FNAB was not deemed suitable for surgical intervention and was instead directed to stereotactic radiotherapy due to the observation of EEG changes during balloon occlusion testing. Four years after stereotactic radiotherapy, the

patient underwent surgery because of the growth and symptomatic presentation of the mass. The final pathology of the excised tumor revealed a schwannoma. In conclusion, 1 patient had a single preoperative session of stereotactic radiotherapy, and 2 patients had a single postoperative session of stereotactic thyroplasty. In the follow-up of the patients who received stereotactic radiosurgery after the operation, residual tumors did not grow.

In 17 of 40 patients (42.5%) who underwent tumor excision, neurological deficits were detected in the nerve of origin following surgery. In the postoperative period, 3 patients had a minimal loss of upper limb motor function. 4 patients had facial nerve paralysis, 3 patients had vagus nerve paralysis, and 1 patient complained of numbness at the apex of the tongue. 3 patients had Horner's syndrome. Postoperative ptosis was observed in two patients with vagal schwannoma and one patient who had undergone surgery for cervical plexus schwannoma.

During the follow-up period, 3 patients who had experienced a loss of upper limb motor function received physical therapy and rehabilitation and subsequently reported an improvement in their strength and functional abilities. Postoperative 7-12 cranial nerve transfer was performed in 2 patients with tympanic cavity schwannomas. A cable graft interposition with the great auricular nerve was performed intraoperatively in 1 patient with facial schwannoma after the excision of the tumor, and a gold weight implantation was performed 3 months later during the follow-up period. The patient had grade 3 facial paralysis and no resting asymmetry. One of the 2 patients with vagal schwannoma and postoperative unilateral vocal cord paralysis underwent type 1 thyroplasty; the other patient had no voice and aspiration problems. A patient who had Horner's syndrome underwent levator muscle resection as a surgical procedure during the postoperative follow-up period due to ptosis. Partial improvement was observed in other patients with ptosis.

DISCUSSION

Schwannomas are benign, well-differentiated, solid or cystic, well-differentiated neoplasms originating

from Schwann cells of the cranial nerves, except the optic and olfactory nerves, which lack Schwann cells. They are located adjacent to the nerve of origin. While the literature generally reports a similar prevalence in both sexes, we found a higher frequency in women (female/male ratio of 2.2), which is similar to the findings of Zhang et al.^{2,6,7} The mean age in our study was 39.08 years, which is consistent with the literature. The parapharyngeal region was the most common tumor location (26.6%) in our study. Malone et al. also reported that the most common anatomic site of the tumor in their series was the parapharyngeal region, with 31% of cases.³

One of the difficulties in treating schwannomas is that it is not always possible to make the correct diagnosis before surgery. In most patients, the initial symptom is painless swelling in the neck. However, neurological symptoms associated with the nerve of origin may also manifest. The location of a mass can influence the presentation of symptoms. Those located within expansive spaces, such as the neck and parapharyngeal region, may not result in noticeable manifestations. Conversely, those confined within narrower areas, including the middle ear and skull base, can lead to neurological symptoms and signs.³ Consistent with this observation, 2 of the 4 patients with schwannomas located in the tympanic cavity in our series had preoperative facial paralysis and conductive hearing loss.

Preoperative imaging modalities are beneficial for surgical planning because they reveal the location and size of the tumor and its relationship with the surrounding neurovascular structures. MRI is the imaging modality of 1st choice for diagnosis and surgical planning. Schwannomas demonstrate a hypointense signal on T1 images and a heterogeneous hyperintense signal on T2 images, along with intense and heterogeneous gadolinium uptake.^{8,9} Liu et al. reported in their case series that imaging techniques (CT or MRI) were able to diagnose possible schwannomas preoperatively in 38% of cases.⁹ On the other hand, Çakır et al. reported that MRI findings were suggestive of the diagnosis of schwannoma in all patients (100%) in their case series.¹⁰ The relationship of the internal carotid and internal jugular veins with the mass is helpful in the diagnosis of schwannomas

located in the parapharyngeal region.¹¹ The salt and pepper appearance seen in paraganglioma on MRI is helpful in the differentiation of schwannoma from paraganglioma.¹² Superior vagal tumors displace the internal carotid artery anteromedially toward the pharynx and displace the internal jugular vein laterally, separating the internal carotid artery from the internal jugular vein.¹³ In tumors arising from the superior sympathetic nerves, both the internal carotid artery (ICA) and the jugular vein are pushed anterolaterally. Differential diagnosis is more difficult in the lower cervical region. Although imaging methods are very useful, it is not always possible to make a diagnosis using imaging alone.

FNAB may be used for diagnosis. However, its sensitivity and specificity are low in the diagnosis of schwannomas. Kang et al. and Liu et al. reported that they were able to diagnose schwannomas in 20% of patients with preoperative FNAB.^{9,14} The appearance of characteristic Verocay bodies is helpful in the diagnosis of schwannoma by cytology.¹⁴ In our study, preoperative FNAB was performed in 21 patients and 9 (42.8%) of them were reported as schwannoma. The FNAB result was nondiagnostic in 8 patients, suspicious for malignancy in 2 patients, fibroadipous tissue with chronic inflammation in 1 patient, and paraganglioma in 1 patient. The definitive diagnosis is made histologically by the presence of characteristic Antoni A and Antoni B patterns and S-100 immunohistochemical staining.¹⁴ Ahn et al. reported that core needle biopsy has a higher accuracy than FNAB without increased complication rates.¹⁵

Although the definitive treatment for schwannomas is surgery, there are several treatment options. Follow-up, radiotherapy, and surgery are the main options. Surgical excision may result in additional morbidities, particularly in cases of schwannomas originating from the vagal nerve, facial nerve, and brachial plexus. On the other hand, it has also been noted that the tumor may remain stable in patients with vestibular schwannoma who were followed up without any intervention.¹⁶ For this reason, some authors recommend the follow-up of asymptomatic patients until the onset of symptoms.^{17,18} Follow-up is an option that can be considered especially in asymptomatic patients, elderly patients, and patients who

are not suitable for surgery. Yafit et al. suggested follow-up for asymptomatic patients in their algorithm for treating schwannomas.¹⁸ In our case series, in 3 patients (1 facial schwannoma, 1 vagal schwannoma, 1 brachial plexus schwannoma) who were not symptomatic preoperatively, who had no nerve paresis or paralysis, who were operated on with different pre-diagnoses, but who were found to have schwannomas during surgery, we terminated surgery because of the prediction of paralysis after excision and decided to follow up after discussing possible complications with the patients. The tumor size of the patient with vagal schwannoma was 51x31 mm in 2021 and 66x37 mm in the current imaging in 2024, but the patient had no active symptoms. The other 2 patients with brachial and facial schwannomas were followed up for 1 year and 3 months, respectively, with no progression or active symptoms.

There are different surgical approaches. Depending on the location and size of the mass, trans-cervical, transoral, intranasal, lateral rhinotomy, postauricular, or combined approaches may be used. Some authors recommend extracapsular excision to prevent tumor recurrence.⁵ However, because of the better preservation of nerve function and because it does not change recurrence rates, some authors suggest intracapsular excision.^{13,19} Obholzer et al. claimed that when intracapsular excision is performed in the correct surgical plan, it is not a sub-complete resection but can be defined as a complete resection and nerve function can be preserved at the same time.¹⁹ Intracapsular enucleation has been used especially for tumors originating from major nerves such as the brachial plexus and vagus nerve. In our case series, we performed intracapsular enucleation in one brachial plexus schwannoma and three vagal schwannomas. However, postoperative vagus paralysis occurred in a patient with vagal schwannoma despite intracapsular enucleation. One patient with brachial plexus schwannoma who underwent intracapsular enucleation had mild postoperative weakness but recovered with physical therapy.

Intermittent or continuous intraoperative nerve monitoring is advised in the modern surgical approach for schwannomas. It has been suggested that the mapping of nerve fibers on the capsule may re-

duce complication rates, especially for schwannomas arising from motor nerves.^{4,5} However, nerve monitoring is not beneficial in tumors originating from the sympathetic and sensory nerves. We also used intra-operative nerve monitoring for the facial, vagal, and brachial plexus schwannomas in our case series.

Radiotherapy is over 90% effective in halting tumor growth in vestibular schwannomas.⁵ The role of radiotherapy in head and neck schwannomas is quite limited compared with that in vestibular schwannomas. Radiotherapy is recommended as the primary treatment modality for symptomatic patients who are not candidates for surgery.¹⁸ The long-term effects of radiotherapy should be considered, especially in young patients. A patient with recurrent schwannoma of the infratemporal fossa was treated with stereotactic radiosurgery after the 2nd subtotal resection. A patient with facial schwannoma whose intraoperative frozen section result revealed a malignant mesenchymal tumor was treated with stereotactic radiosurgery after the definitive pathology result was schwannoma. There was no growth of residual tumors in the follow-up of the patients after stereotactic radiosurgery who were followed up for 4-13 years, respectively.

There are very little data in the literature regarding the recurrence of head and neck schwannomas, and it is quite rare.^{2,9} In our case series, 1 patient with an infratemporal fossa schwannoma extending into the cavernous sinus who underwent subtotal excision was reoperated 8 years later due to enlargement of the residual tumor. The 1st operation was performed via open infratemporal fossa surgery and craniotomy, whereas the second operation was performed endoscopically by our skull base surgery team. The aforementioned patient had no residual tumor growth after stereotactic radiosurgery.

The management of nerve paralysis following surgery for schwannomas is also part of the treatment.⁹ If it is not possible to preserve the nerve during surgery, microsurgical techniques such as end-to-end anastomosis or nerve graft transposition may be used after tumor resection. For vagal schwannomas, if there is hoarseness and aspiration after surgery, medialization thyroplasty, for facial schwan-

nomas, repair with cable graft during surgery, gold implant, 7-12 nerve anastomosis or facial reanimation can be performed after removal of the schwannoma. Levator muscle resection may be performed for symptomatic patients with Horner's syndrome and ptosis. For brachial plexus schwannomas, physical therapy may be beneficial if there is a postoperative loss of strength.

The limitations of our study include its retrospective nature and the fact that the patients included in the study were followed up and treated by different surgeons. Prospective studies comparing different surgical techniques and treatments performed by a single surgeon would be beneficial.

CONCLUSION

The clinical presentation of schwannomas may vary depending on the nerve of origin or the localization. Although they are mostly asymptomatic and slow-growing tumors, they may cause significant morbidities due to the compression of the surrounding tissues. Surgery is the preferred treatment option, but due to the close relationship with the nerve of origin, it is not always possible to preserve nerve function. The possibility of neurological deficits after surgery

should be discussed with the patient before the operation, and all treatment options should be reviewed.

Source of Finance

During this study, no financial or spiritual support was received neither from any pharmaceutical company that has a direct connection with the research subject, nor from a company that provides or produces medical instruments and materials which may negatively affect the evaluation process of this study.

Conflict of Interest

No conflicts of interest between the authors and / or family members of the scientific and medical committee members or members of the potential conflicts of interest, counseling, expertise, working conditions, share holding and similar situations in any firm.

Authorship Contributions

Idea/Concept: Mehmet Ekrem Zorlu, Muammer Melih Şahin, Utku Aydil; **Design:** Mehmet Ekrem Zorlu, Muammer Melih Şahin; **Control/Supervision:** Betül Ögüt, Mehmet Düzlü, Utku Aydil; **Data Collection and/or Processing:** Mehmet Barış Okumuş, Metin Emin Demirkan, Betül Ögüt; **Analysis and/or Interpretation:** Metin Emin Demirkan, Mehmet Ekrem Zorlu, Mehmet Barış Okumuş; **Literature Review:** Mehmet Ekrem Zorlu; **Writing the Article:** Mehmet Ekrem Zorlu; **Critical Review:** Betül Ögüt, Mehmet Düzlü, Utku Aydil, Muammer Melih Şahin.

REFERENCES

- Phulware RH, Sardana R, Chauhan DS, Ahuja A, Bhardwaj M. Extracranial schwannomas of the head and neck: a literature review and audit of diagnosed cases over a period of eight years. *Head Neck Pathol.* 2022;16(3):707-15. [Crossref] [PubMed] [PMC]
- Dosemane D, Kabekkodu S, Jaipuria B, Sreedharan S, Shenoy V. Extracranial non-vestibular head and neck schwannomas: a case series with the review of literature. *Braz J Otorhinolaryngol.* 2022;88(Suppl 4):S9-S17. [PubMed] [PMC]
- Malone JP, Lee WJ, Levin RJ. Clinical characteristics and treatment outcome for nonvestibular schwannomas of the head and neck. *Am J Otolaryngol.* 2005;26(2):108-12. [Crossref] [PubMed]
- Ijichi K, Kawakita D, Maseki S, Beppu S, Takano G, Murakami S. Functional nerve preservation in extracranial head and neck schwannoma surgery. *JAMA Otolaryngol Head Neck Surg.* 2016;142(5):479-83. [PubMed]
- Sandler ML, Sims JR, Sinclair C, et al. Vagal schwannomas of the head and neck: a comprehensive review and a novel approach to preserving vocal cord innervation and function. *Head Neck.* 2019;41(7):2450-66. [Crossref] [PubMed]
- Zhang H, Cai C, Wang S, Liu H, Ye Y, Chen X. Extracranial head and neck schwannomas: a clinical analysis of 33 patients. *Laryngoscope.* 2007;117(2):278-81. [Crossref] [PubMed]
- Wilson JA, McLaren K, McIntyre MA, von Haacke NP, Maran AG. Nerve-sheath tumors of the head and neck. *Ear Nose Throat J.* 1988;67(2):103-7, 110. [PubMed]
- Anil G, Tan TY. Imaging characteristics of schwannoma of the cervical sympathetic chain: a review of 12 cases. *AJNR Am J Neuroradiol.* 2010;31(8):1408-12. [PubMed] [PMC]
- Liu HL, Yu SY, Li GK, Wei W. Extracranial head and neck Schwannomas: a study of the nerve of origin. *Eur Arch Otorhinolaryngol.* 2011;268(9):1343-7. [PubMed] [PMC]
- Çakır A, Erdağ TK, Ecevit MC, Güneri EA, Sütay S, İkiz AO. Extracranial head and neck schwannomas: A series of 14 patients. *The Turkish Journal of Ear Nose and Throat.* 2017;27(6):257-263. [Link]
- Saito DM, Glastonbury CM, El-Sayed IH, Eisele DW. Parapharyngeal space schwannomas: preoperative imaging determination of the nerve of origin. *Arch Otolaryngol Head Neck Surg.* 2007;133(7):662-7. [Crossref] [PubMed]

12. Sharma P, Zaheer S, Goyal S, et al. Clinicopathological analysis of extracranial head and neck schwannoma: a case series. *J Cancer Res Ther.* 2019;15(3):659-64. [[Crossref](#)] [[PubMed](#)]
13. Netterville JL, Groom K. Function-sparing intracapsular enucleation of cervical schwannomas. *Curr Opin Otolaryngol Head Neck Surg.* 2015;23(2):176-9. [[PubMed](#)]
14. Kang GC, Soo KC, Lim DT. Extracranial non-vestibular head and neck schwannomas: a ten-year experience. *Ann Acad Med Singap.* 2007;36(4):233-8. [[PubMed](#)]
15. Ahn D, Lee GJ, Sohn JH, Jeong JY. Fine-needle aspiration cytology versus core-needle biopsy for the diagnosis of extracranial head and neck schwannoma. *Head Neck.* 2018;40(12):2695-700. [[PubMed](#)]
16. Stangerup SE, Caye-Thomasen P, Tos M, Thomsen J. The natural history of vestibular schwannoma. *Otol Neurotol.* 2006;27(4):547-52. [[Crossref](#)] [[PubMed](#)]
17. Moukarbel RV, Sabri AN. Current management of head and neck schwannomas. *Curr Opin Otolaryngol Head Neck Surg.* 2005;13(2):117-22. [[Crossref](#)] [[PubMed](#)]
18. Yafit D, Horowitz G, Vital I, Locketz G, Fliss DM. An algorithm for treating extracranial head and neck schwannomas. *European Archives of Oto-Rhino-Laryngology.* 2015;272:2035-2038. [[Crossref](#)] [[PubMed](#)]
19. Obholzer R, Borsetto D, Sandison A. Function preservation for resection of vagal schwannoma of the head and neck: Are we talking about the same technique? *Head & Neck.* 2020;42(11):3469-3470. [[Crossref](#)] [[PubMed](#)]