

Primary Tonsillar Hemangiosarcoma: A Rare Case Report

Primer Tonsil Hemanjiosarkomu: Nadir Bir Olgu Sunumu

*Uygar Levent DEMİR, MD, **Özlem SARAYDAROĞLU, MD, *Metin Yüksel AKYILDIZ, MD, *Osman DURGUT, MD

*Uludağ University Medical Faculty, Department of Otorhinolaryngology Head and Neck Surgery,

** Uludağ University Medical Faculty, Department of Pathology, Bursa

ABSTRACT

Incidence of tonsillar carcinoma is increasing worldwide. Histopathologically the vast majority of tonsillar carcinomas are squamous cell carcinomas and lymphomas. On the other hand, other tumors with different histopathological diagnoses can be identified very rarely. We report a case of 56-year-old woman who presented with unilateral progressive tonsillar enlargement and severe pain. The patient was diagnosed to have primary tonsillar hemanjiosarcoma. To the best of our knowledge this is the first case of primary tonsillar hemangiosarcoma reported in the literature.

Keywords

*Tonsillar neoplasms; hemangiosarcoma;
positron-emission tomography*

ÖZET

Tonsil karsinomları tüm dünyada insidansı hızla artan kanserlerdendir. Histopatolojik olarak büyük çoğunluğunu skuamöz hücreli karsinomlar ve lenfomalar oluşturur. Ancak nadiren farklı histopatolojik tanılar görülebilmektedir. Bu olguda kliniğimize tek taraflı progresif tonsil büyümesi ve şiddetli ağrı ile başvuran 56 yaşındaki bir kadın sunulmuştur. Hasta primer tonsiller hemanjiosarkom tanısı almıştır. Bu olgu literatürde bildirilen ilk primer tonsil hemanjiosarkom vakası olması nedeniyle özelliğlidir.

Anahtar Sözcükler

*Tonsil tümörleri; hemanjiosarkom;
pozitron emisyon tomografi*

Çalışmanın Dergiye Ulaştığı Tarih: **04.01.2012**

Çalışmanın Basıma Kabul Edildiği Tarih: **22.02.2012**



Correspondence

Uygar Levent DEMİR, MD,

Uludağ University Medical Faculty

Department of Otorhinolaryngology Head and Neck Surgery,

16069 Gorukle, Nilufer-Bursa, TURKEY

Fax: +90 (0224) 4428091

E-mail: uygardemir@hotmail.com

Tel: +90 (0224) 2952641

INTRODUCTION

Oral cavity cancers including tonsillar carcinoma are the second in frequency after larynx in the head and neck region. The incidence of tonsillar carcinoma has been reported to increase worldwide since last 2-3 decades.¹⁻³ Histopathologically the vast majority of tonsillar carcinomas are derived from squamous epithelial cells' differentiation, and are squamous cell carcinomas. The second most common cancer is lymphoma which also derived from lymphoid portion of tonsils.⁴ In addition, tumors with different histopathological diagnoses have been shown in previous reports due to distant metastases from gastrointestinal system, lung, breast or even uterus.⁵⁻¹⁰ In this case, we presented a very rare case with primary tonsillar hemangiosarcoma of right tonsil.

CASE REPORT

A 56-year-old woman was admitted to the department of otolaryngology with the complaints of odynophagia, swelling of right tonsil and difficulty of swallowing. These symptoms had already been present for almost 2 months. She had given antibiotics for tonsillar infection previously in a different ENT clinics but failed to respond. A magnetic resonance imaging (MRI) of the neck showed a well delineated right tonsillar mass of 3x3 cm which pushed the parapharyngeal structures laterally and oropharyngeal space medially. The mass was reported to invade masticator muscles and no pathological lymph nodes were present (Figure 1 and 2). Later she was referred to our department for further diagnosis and treatment with a suspicion of tonsillar malignancy.

On admission, detailed physical examination of the patient revealed a diffuse right tonsillar swelling on which multiple ulcerated hemorrhagic lesions over bulky lobulations were present. There was no palpable mass at neck examination. A right tonsillectomy was immediately performed in order to obtain definitive histopathological diagnosis. The patient was discharged from the hospital after 1 day and no complication was observed during hospitalization. The biopsy of tonsillar mass revealed a hemangiosarcoma of tonsillar tissue.

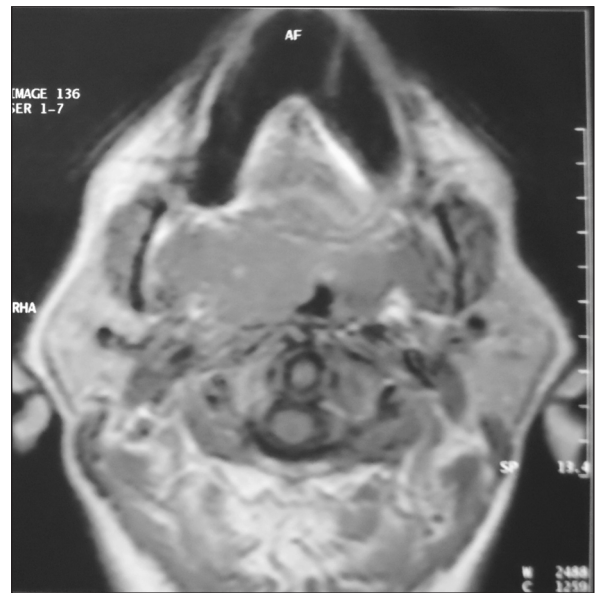


Figure 1. Axial plane MR imaging of the patient showing right tonsillar mass of 3x3cm.

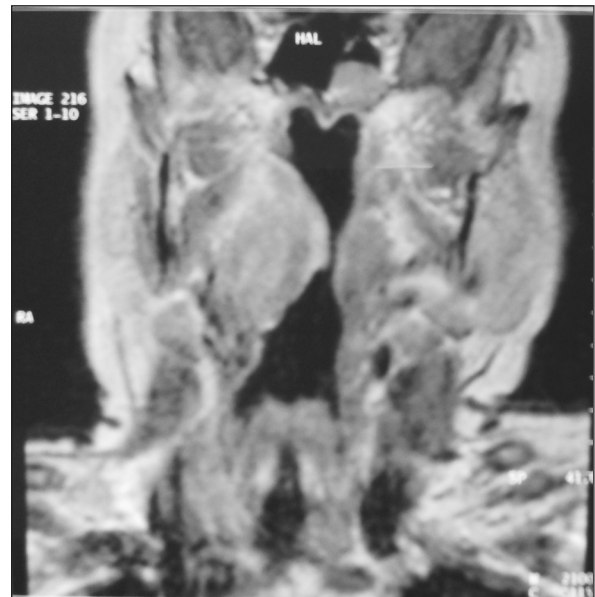

Figure 2. The coronal plane MR imaging showing oropharyngeal space narrowed by mass effect.

Histopathological evaluation of biopsy material showed atypical cells observed in angiosarcoma (Figure 3). Positive staining of tumoral cells with CD34 was seen in Figure 4. The increased prolifera-

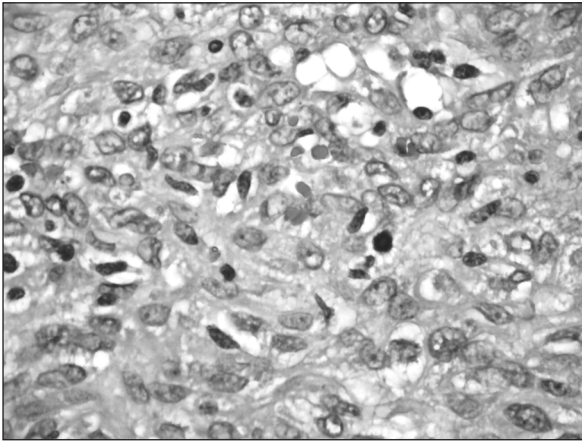


Figure 3. Picture shows atypical cells observed in angiosarcoma (HEx200).

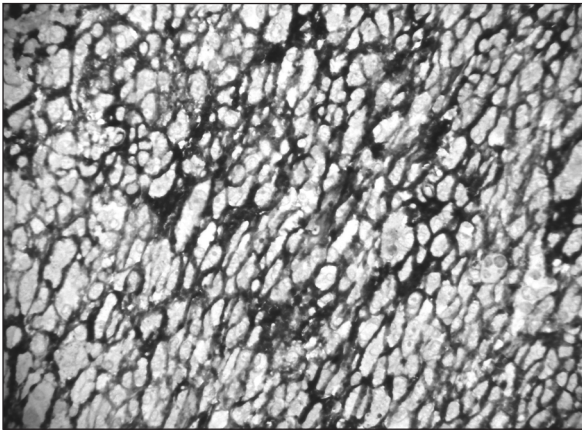


Figure 4. Picture demonstrating positive staining of tumoural cells with CD34 (CD34x200).

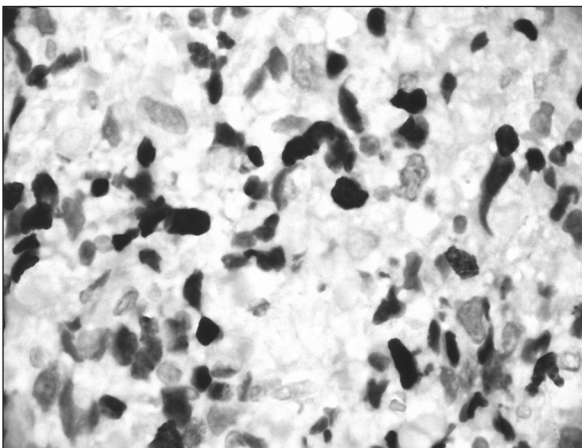


Figure 5. Picture reveals increased proliferative activity with Ki 67 staining (Ki 67x200).

tive activity with Ki 67 staining was obviously indicating aggressive behavior of tumoural cells (Figure 5).

To eliminate the possibility of metastasis from a distant organ we decided to perform a whole body PET/CT scan of the patient. The patient later underwent PET/CT imaging study and it revealed an ipsilateral hypermetabolic cervical mass at level 2 (SUVmax 4.12) and also increased metabolic activity at left tonsillar region (SUVmax 6.7) which was interpreted as inflammatory. There were no other areas which showed increased FDG uptake and metabolic activity. These findings confirmed that tonsillar malignancy was primary in origin. The patient was discussed for further treatment in head and neck oncology council of medical faculty and an adjuvant chemoradiotherapy was planned. The patient was later informed about her disease progress and potential morbidity of the treatment modalities and a signed informed consent form was obtained. The patient was transferred to the oncology department with the diagnosis of primary heman-giosarcoma of tonsil. She was reexamined after 2 weeks of surgery. There was no residual tumoural tissue on right surgical bed and complete healing was observed on mucosal surface.

DISCUSSION

Incidence of tonsillar carcinoma is constantly increasing. Beside common causes like alcohol consumption and tobacco use, human papilloma virus association was accepted as a major risk factor in the recent years.^{1,2} Fortunately, recent advances in imaging modalities like PET/CT enabled early detection of primary site and correct staging by showing distant metastasis.¹¹

Tonsillar asymmetry is a major concern for otolaryngologists since there was no consensus whether biopsy is indicated in every case. Some authors believed that tonsillar asymmetry should be accepted as an important sign for malignancy and they recommended urgent tonsillectomy to rule out this possibility.^{12,13} Meanwhile others stated that routine histopathological examination for asymmetry was not warranted for otherwise normal looking tonsils if there was no accompanying symptoms such as chronic pain, dysphagia, progressive enlargement or presence of high clinical

suspicion like mucosal abnormality, ulceration or cervical lymphadenopathy.¹⁴⁻¹⁷ Certainly, the main challenge arises while counseling to patients who have asymmetrical tonsillar enlargement with normal mucosal covering, with no cervical lymph node and pain. In our case the patient revealed most of the malignancy indicators like progressive enlargement, difficulty of eating and ulcerative lesions on an asymmetrically tonsil. Tonsillectomy for histopathological examination was inevitable for our patient and biopsy report confirmed presence of the malignancy.

Although all clinical findings before surgery were suggestive of malignancy, the histopathological diagnosis was surprising: hemangiosarcoma of tonsillar tissue. Although there are various histopathological types of tonsillar malignancies, nearly three quarters composed of squamous cell carcinomas and remainder are mostly lymphomas.⁴ Some rare cases of different

histopathologies were also reported in the literature.^{5,8,9,18} To best of our knowledge there is only one case in English literature, reporting the presence of hemangiosarcoma at tonsil.¹⁰ But in that case the patient had a primary breast hemangiosarcoma with tonsillar metastasis. In our case the patient was also diagnosed to have tonsillary hemangiosarcoma but as shown in PET/CT evaluations of the patient, there was no other area demonstrating hypermetabolic activity. This is the first case of a primary tonsillar hemangiosarcoma reported in the literature.

In conclusion, although different histopathological diagnosis other than squamous cell carcinoma and lymphoma are very rare, one should consider the possibility of atypical pathological diagnosis. Also immediate tonsillectomy is indicated in patients who showes asymmetrical tonsillar enlargement accompanied with suspicious clinical findings and symptoms for malignancy.

REFERENCES

- Hocking JS, Stein A, Conway EL, Regan D, Grulich A, Law M, Brotherton JM. Head and neck cancer in Australia between 1982 and 2005 show increasing incidence of potentially HPV-associated oropharyngeal cancers. *Br J Cancer* 2011; 104(5):886-91.
- Olaleye O, Moorthy R, Lyne O, Black M, Mitchell D, Wiseberg J. A 20-year retrospective study of tonsil cancer incidence and survival trends in South East England: 1987-2006. *Clin Otolaryngol* 2011;36(4):325-35.
- Hammarstedt L, Lu Y, Marklund L, Dalianis T, Munck-Wikland E, Ye W. Differential survival trends for patients with tonsillar, base of tongue and tongue cancer in Sweden. *Oral Oncol* 2011;47(7):636-41.
- Hyams VJ. Differential diagnosis of neoplasia of the palatine tonsil. *Clin Otolaryngol Allied Sci* 1978;3(2):117-26.
- Struijs B, de Bree R, van Groeningen CJ, Mooi WJ, Leemans CR. Tonsillar metastasis of oesophageal adenocarcinoma. *Eur Arch Otorhinolaryngol* 2008;265(1):127-9.
- Yamaguchi E, Uchida M, Makino Y, Tachibana M, Sato T, Yamamoto Y, Kawashima K, Araki A, Maruyama R. Tonsillar metastasis of gastric cancer. *Clin J Gastroenterol* 2010; 3(6):289-295.
- Park KK, Park YW. Tonsillar metastasis of signet-ring cell adenocarcinoma of the colon. *Ear Nose Throat J* 2010;89(8): 376-7.
- Zepiridis L, Zafrakas M, Theodoridis TD, Kaplanis K, Dinas KK, Bontis JN. A unique case of palatine tonsil metastasis from endometrial cancer. *Eur J Gynaecol Oncol* 2009;30(2): 229-30.
- Hisa Y, Yasuda N, Murakami M. Small cell carcinoma of the lung metastatic to the palatine tonsil. *Otolaryngol Head Neck Surg* 1997;116(4):563-4.
- Bar R, Netzer A, Ostrovsky D, Daitzchman M, Golz A. Abrupt tonsillar hemorrhage from a metastatic hemangiosarcoma of the breast: case report and literature review. *Ear Nose Throat J* 2011;90(3):116-20. Review.
- Mannina EM, Pejavar SM, Glastonbury CM, van Zante A, Wang SJ, Yom SS. Diagnosis of Bilateral Tonsil Cancers via Staging PET/CT: Case Report and Review. *Int J Otolaryngol Epub* 2011 Jul 14.
- Oluwasanmi AF, Wood SJ, Baldwin DL, Sipaul F. Malignancy in asymmetrical but otherwise normal palatine tonsils. *Ear Nose Throat J* 2006;85(10):661-3.
- Beatty MM, Funk GF, Karnell LH, Graham SM, McCulloch TM, Hoffman HT, Robinson RA. Risk factors for malignancy in adult tonsils. *Head Neck* 1998;20(5):399-403.
- Puttasiddaiah P, Kumar M, Gopalan P, Browning ST. Tonsillectomy and biopsy for asymptomatic asymmetric tonsillar enlargement: are we right? *J Otolaryngol* 2007;36(3): 161-3.

15. Sunkaraneni VS, Jones SE, Prasai A, Fish BM. Is unilateral tonsillar enlargement alone an indication for tonsillectomy? *J Laryngol Otol* 2006;120(7):E21.
16. Cinar F. Significance of asymptomatic tonsil asymmetry. *Otolaryngol Head Neck Surg* 2004;131(1):101-3.
17. Syms MJ, Birkmire-Peters DP, Holtel MR. Incidence of carcinoma in incidental tonsil asymmetry. *Laryngoscope* 2000;110(11):1807-10.
18. Ozbudak IH, Guney K, Mutlu D, Gelen T, Ozbilim G. Bilateral tonsillar and esophageal Kaposi sarcoma in an HIV-negative patient. *Ear Nose Throat J* 2011;90(7):E23-6.