KBB ve BBC Dergisi 21 (1):30-3, 2013

The Use of Temporalis Muscle Pedicled Flap for Reconstruction of Extensive Cheek Defects

Geniş Yanak Defektlerinin Onarımında Temporal Kas Pediküllü Flep Kullanımı

***Erdinç AYGENÇ, MD, **Rıza Önder GÜNAYDIN, MD, **Erdem GÜR, MD, **Serdar ÇELİKKANAT, MD, **Cafer ÖZDEM, MD**

* Güven Hospital, Clinic of Otolaryngology and Head and Neck Surgery,
** Numune Training and Research Hospital, Clinic of 2nd Otolaryngology and Head and Neck Surgery, Ankara

ABSTRACT

Objective: To present the experience using temporal muscle pedicled flaps for the reconstruction of extensive cheek defects after cancer surgery.
Material and Methods: Temporalis muscle pedicled flap was applied for the repair of extensive cheek defects in four patients after surgical excision due to malignant lesion. The sizes of defects, post-surgical complications and surgical outcomes were evaluated retrospectively.
Results: There was no evidence of flap failure in any of the patients. One patient experienced minor partial flap necrosis that required a subsequent debridement. Temporary facial nerve palsy involving the frontal branch of the facial nerve was observed in one patient.
Conclusion: Temporalis muscle pedicled flap can be a good alternative in the reconstruction of wide cheek defects with reasonable aesthetic problems occurring at the donor site.

Keywords
Surgical flaps; cheek; carcinoma; squamous cell; melanoma

ÖZET

Amaç: Yanakta, kanser cerrahisi sonrasında oluşan geniş defektlerin onarımında pediküllü temporal kas flebinin sonuçlarının incelenmesidir.
Gereç ve Yöntemler: Yanakta yerleşimli malign tümör nedeniyle cerrahi tedavi uygulanan ve doku kaybının onarımında pediküllü temporal kas flebi kullanılan dört olgumuzun retrospektif olarak doku kaybı boyutları ve postoperatif komplikasyonları incelendi ve cerrahi sonuçları değerlendirildi.
Bulgular: Opere edilen olgularımızın ikisinde yassı hücreli karsinom, birinde bazal hücreli karsinom ve birinde malign melanom tanısı mevcuttu. Hastaların hiçbirinde tüm flep kaybı gözlenmedi. Bir hastada debridman gerektiren minör kısmi flep nekrozu ve bir hastada fasiyal sinirin frontal dalında geçici paralizi ile karşılaşıldı.
Sonuç: Pediküllü temporal kas flebi geniş yanak doku kaybı onarımında kullanılabilen, kabul edilebilir kozmetik sonuçları olan bir seçenektir.

Anahtar Sözcükler
Cerrahi flepler; yanak; karsinom; skuamoz hücre; melanom

Çalışmanın Dergiye Ulaştığı Tarih: **05.01.2012** Çalışmanın Basıma Kabul Edildiği Tarih: **04.03.2013**

≈

Correspondence
Rıza Önder GÜNAYDIN , MD
Numune Training and Research Hospital,
Clinic of 2nd Otolaryngology and Head and Neck Surgery,
Ankara
E-mail: rogunaydin@gmail.com

INTRODUCTION

Skin cancers are the most frequently seen heterogeneous group of tumours among all malignancies. More than two million new cases of basal or squamous cell carcinomas, approximately 68,000 melanomas, and 6000 non-epithelial skin cancers occur yearly in the United States.[1] Approximately 90% of the non-melanoma skin cancers and 20% of malignant melanomas in the human body present at the head and neck region.[2,3] Primary treatment of the skin cancers in the head and neck area is surgical excision and reconstruction with primary suturation, split- or full-thickness skin grafts, local flaps, and regional or distant micro vascular free flaps.[4,5]

The temporalis muscle pedicled flap (TMPF) was first described in 1895 by Lentz, who used it after the resection of the condyle neck for temporomandibular joint ankylosis. Subsequently, this flap has been described for the reconstruction of wide and complex defects involving the periorbital, mastoid, maxillary and skull base regions, oral cavity, oropharynx and nasopharynx.[6,7]

The aim of this study is to evaluate TMPF after cancer surgery for the reconstruction of extensive cheek defects in light of the literature and with our experience of four cases.

MATERIAL AND METHODS

Four patients whose cheek defects were reconstructed with TMPF were retrospectively reviewed. All patients were systemically examined with CT and MRI and no metastatic lesion was found. The anatomy and surgical technique of TMPF have already been well described in the literature.[6-8] In order to facilitate the rotation of the flap and to avoid pedicle injury, the zygomatic arch was routinely removed in each patient. Osteotomies were performed following the opening of predrilling holes, followed by the subsequent fixation with miniplates. 3.0 or 4.0 vicryl sutures were used for reconstruction and a split thickness skin graft harvested from lateral thigh was applied for each subject (Figure 1).

RESULTS

Patients' age, gender and pathological diagnosis data are listed in Table 1. The mean patient age was 72.5 (67-78) years. Mean follow-up time was 25 months (6 months-6 years). The mean width of the defects was 6.0 cm ± 2.0 cm, and mean defect length was 3.0 cm ± 1.5cm. Two patients underwent additional therapy after surgery (Patient 1 and 4). Patient 1 received adjuvant radiotherapy (6000 Gy) to the primary site due to the presence of neural and vascular invasion. Systemic chemotherapy and interferon therapy were applied to patient 4. Patients 2 and 3 did not receive any additional therapies.

One patient experienced partial minor flap necrosis which required debridement. One of the patients,

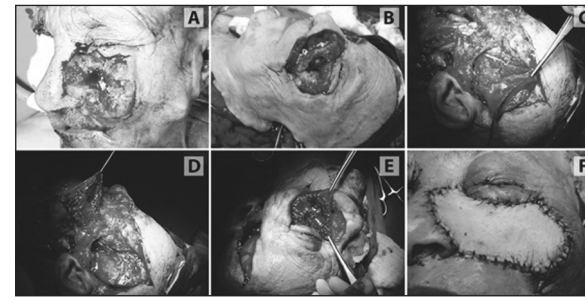

Figure 1. A. Squamous cell carcinoma of the cheek and metastatic lymph node in the parotid gland. **B.** Cheek defect after resection. Due to invasion of the infraorbital nerve by the tumor, nerve was sacrificed with surrounding bone tissue. **C.** Left-sided pedicled temporalis muscle flap was raised. **D.** Flap has been rotated to the cheek defect. Fascia of the temporalis muscle tailored over bone defect. **E.** The soft tissue defect was reconstructed by the flap. **F.** Split thickness skin flap was used for covering the flap.

Table 1. Patients' information including gender and age data, operation performed and pathology of the lesions.

Patients	Gender	Age	Pathology	TNM stage	Operation
1	F	78	SCC	T4aN2aMo	Exc.+TP+MRND
2	F	72	SCC	T3NoMo	Exc.
3	F	67	BCC	T4NoMo	Exc.
4	M	73	MM	T3N1aMo	Exc.+TP+MRND

F: Female; M: Male; SCC: Squamous cell carcinoma; BCC: Basal cell carcinoma; MM: Malignant melanoma; Exc: Excision; TP: Total parotidectomy; MRND: Modified radical neck dissection (type III).

who received adjuvant radiation therapy after surgery, was found to have an infection around the mini-plates and received antibiotic therapy. Mini plate was subsequently removed with full resolution of the infection. Another patient experienced temporary facial nerve palsy involving the frontal branch of the facial nerve, which took approximately six months to recover. There were no major complications or mortality due to the procedure performed.

DISCUSSION

TMPF is an approximately 0.5-1.0 cm thick and 12-16 cm long flap which is known to have a versatile and abundant blood supply. The degree of rotation tolerated by the pedicle of TMPF is 130 degrees.[9,10] TMPF, has a reliable and constant vascularisation, is accessible through a prolonged lazy-S incision and lies in the same operative field. Because of these features, this flap can easily be tailored to provide reconstruction of wide cheek defects. However, the flap cannot be used if the ipsilateral internal maxillary or the external carotid arteries are sacrificed.[7] Permanent injury to the facial nerve and flap loss are the major complications of this flap. Minor complications include infection, seroma, hematoma, temporary nerve palsy, hair loss, trismus, and aesthetic donor site issues.[6,8,11-13] In the largest published case series of TMPF, Clauser et al. reported that postoperative paresis and paralysis of the temporal branch were 19.2% and 2.7%, respectively.[6] In the same study, total necrosis of the flap was shown to occur rarely (1.6%) and partial flap loss was seen only in 13.4% of the cases. In cases where parotidectomy became necessary during the preparation and rotation of the flap, facial nerve injury is less likely. When parotidectomy is not necessary, injury at the branches of the facial nerve can be avoided by elevating the temporal fat pad with a scalp flap as described in the literature. This procedure is known to protect the nerve within the temporoparietal fascia.[8] Nerve injury can be seen as a result of traction during the elevation of the flap and removal of the zygomatic arch. In our patients, frontal branch palsy occurred in one case where parotidectomy was not performed. There was no flap loss in our patients, and one patient had partial dehiscence of the flap.

Another major problem with TMPF is temporal hollowing. It's the most commonly cited morbidity related to donor site aesthetics.[6-9] This is an important problem especially in male patients, while female patients can easily mask the hollowing with their hair at the postoperative period. Cheek defects may require the full length of TMPF for reconstruction but may not need the full width because of the pivot point of the flap just beneath the zygomatic arch. Therefore, if the anterior one third of muscle is kept without elevation, hollowing of the temporal region will be minimized. Resection of the zygomatic arch followed by mini-plate fixation facilitates flap rotation and minimizes trauma to the flap during placement to the cheek. Cordeiro and Wolfe suggested the following in order to minimize donor site aesthetic morbidity: rotating the temporal fat pad into the anterior temporal region, harvesting a large pericranial flap from the frontal and contralateral parietal regions and folding them into the defect and reconstruction of the defect with bone or cartilage grafts.[14] Cartilaginous ribs, bone grafts, rolled dermis, fat tissue, free flaps and alloplastic materials were reported to be used to fill the temporal defects in different series in the literature.[6,8] In our experience, proper replacement of the zygomatic arch prevents the occurrence of a major depression in the non-hair-bearing region of the donor site and preserving the normal position of the temporal fat pad as well as the anterior portion of the temporalis muscle almost eliminates any additional hollowing. Also this flap needs a split thickness skin graft to cover its surface which might cause discoloration in some patients.

There are several techniques described in the literature for reconstruction of the cheek defects including skin grafting, primary closure, local, locoregional advancement rotation, pedicled and free flaps.[15,16] Primary closure is preferred if possible. Cervicofacial advancement flaps are the workhorse rotational flaps for medium to large cheek skin defects.[17] They have good color and texture matching with the cheek. Complications such as marginal flap necrosis, lower eyelid ectropion and hematoma might be encountered.[18] Combination of the classic Mustarde´ cheek rotation flap with a temporoparietal scalp flap and platysma myocutaneous rotation flap are recently described rotational flaps for cheek reconstruction.[19,20] Horta and colleagues have published their experience with TMPF in reconstruction of eight patients with middle third facial defects.[21] They experienced one partial necrosis with dehiscense of the flap after local infection. The authors state that flap vascularity is reliable and flap is useful for covering bone and vital structures.

Also Yücel et al. demonstrated their experience of temporalis muscle flap used in the reconstruction of fa-

cial defects and stated that it is an effective flap for large defects of maxilla and cheek.[22]

CONCLUSION

TMPF, has a reliable and constant vascularisation, is accessible through a prolonged lazy-S incision and lies in the same operative field. However, the requirement for split thickness skin grafting and osteotomy and mini plate application to zygomatic arc makes it impractical. Although the best choice for cheek defects is primary closure, TMPF may be an alternative rotational flap for the reconstruction of wide defects following maxillo-facial surgery.

REFERENCES

1. Jemal A, Siegel R, Xu J, Ward E. Cancer statistics, 2010. CA Cancer J Clin 2010;60(5):277-300.
2. McGuire JF, Ge NN, Dyson S. Nonmelanoma skin cancer of the head and neck I: histopathology and clinical behavior. Am J Otolaryngol 2009;30(2):121-33.
3. Larson DL, Larson JD. Head and neck melanoma. Clin Plast Surg 2010;37(1):73-7.
4. Ge NN, McGuire JF, Dyson S, Chark D. Nonmelanoma skin cancer of the head and neck II: surgical treatment and reconstruction. Am J Otolaryngol 2009;30(3): 181-92.
5. Kienstra MA, Padhya TA. Head and neck melanoma. Cancer Control 2005;12(4):242-7.
6. Clauser L, Curioni C, Spanio S. The use of the temporalis muscle flap in facial and craniofacial reconstructive surgery. A review of 182 cases. J Craniomaxillofac Surg 1995; 23(4):203-14.
7. Hanasono MM, Utley DS, Goode RL. The temporalis muscle flap for reconstruction after head and neck oncologic surgery. Laryngoscope 2001;111(10):1719-25.
8. Tan O, Atik B, Ergen D. Temporal flap variations for craniofacial reconstruction. Plast Reconstr Surg 2007;119(7): 152e-63e.
9. Bradley P, Brockbank J. The temporalis muscle flap in oral reconstruction. A cadaveric, animal and clinical study. J Maxillofac Surg 1981;9(3):139-45.
10. Koranda FC, McMahon MF, Jernstrom VR. The temporalis muscle flap for intraoral reconstruction. Arch Otolaryngol Head Neck Surg 1987;113(7):740-3.
11. Smith JE, Ducic Y, Adelson R. The utility of the temporalis muscle flap for oropharyngeal, base of tongue, and nasopharyngeal reconstruction. Otolaryngol Head Neck Surg 2005;132(3):373-80.
12. Hüttenbrink KB. Temporalis muscle flap: an alternative in oropharyngeal reconstruction. Laryngoscope 1986;96(9 Pt 1):1034-8.
13. Alonso del Hoyo J, Fernandez Sanroman J, Gil-Diez JL, Diaz Gonzales Fj. The temporalis muscle flap: An evaluation and review of 38 cases. J Oral Maxillofac Surg 1994; 52(2):143-7.
14. Cordeiro PG, Wolfe SA. The temporalis muscle flap revisited on its centennial: advantages, newer uses, and disadvantages. Plast Reconstr Surg 1996;98(6):980-7.
15. Jowett N, Mlynarek AM. Reconstruction of cheek defects: a review of current techniques. Curr Opin Otolaryngol Head Neck Surg 2010;18(4):244-54.
16. Ayhan S, Tuncer S, Özmen S. Tam kat yanak defektinin çift tabakalı serbest torakodorsal arter perforatör flebiyle rekonstrüksiyonu. Türk Plastik Rekonstrüktif ve Estetik Cerrahi Dergisi 2007;15(1):15-18.
17. Rapstine ED, Knaus WJ 2nd, Thornton JF. Simplifying cheek reconstruction: a review of over 400 cases. Plast Reconstr Surg 2012;129(6):1291-9.
18. Tan ST, MacKinnon CA. Deep plane cervicofacial flap: a useful and versatile technique in head and neck surgery. Head Neck 2006;28(1):46-55.
19. Belmahi A, Oufkir A, Bron T, Ouezzani S. Reconstruction of cheek skin defects by the 'Yin-Yang' rotation of the Mustarde flap and the temporoparietal scalp. J Plast Reconstr Aesthet Surg 2009;62(4):506-9.
20. Puxeddu R, Dennis S, Ferreli C, Caldera S, Brennan PA. Platysma myocutaneous flap for reconstruction of skin defects in the head and neck. Br J Oral Maxillofac Surg 2008; 46(5):383-6.
21. Horta RM, Barbosa R, Marques M, Rebelo M, Ferreira A, Reis JC, Amarante JM. Reconstruction of middle third defects of the face with the temporal flap. Ann Plast Surg 2009;63(3):288-91.
22. Yücel A, Yazar Ş, Seradjmir M, Aydın Y, Altıntaş M. Tümör Rezeksiyonu Sonrası Yüzde Oluşan Defektlerin Rekonstrüksiyonunda Temporal Adele Flebi. XXI. Ulusal Plastik, Rekonstrüktif ve Estetik Cerrahi Kongresi, Program ve Özet Kitabı 23, Kuşadası, 1999.