

# A Life Threatening Cervical Necrotizing Fasciitis

## Hayatı Tehdit Eden Agresif Servikal Nekrotizan Fasiit

\*Hazan BAŞAK, MD, \*Ozan Bağış ÖZGÜRSOY, MD, \*Mahmut DEMİRTAŞ, MD,  
\*\*Özlem Selvi CAN, MD, \*\*\*Savaş SEREL, MD, \*Cem MEÇO, MD

\* Ankara University Medical Faculty, Department of Otolaryngology and Head and Neck Surgery,

\*\* Ankara University Medical Faculty, Department of Anesthesiology,

\*\*\* Ankara University Medical Faculty, Department of Plastic and Reconstructive Surgery, Ankara

---

### ABSTRACT

---

Necrotizing fasciitis (NF) is a fatal soft tissue infection causing necrosis of the subcutaneous tissue and fascial planes. It may have systemic manifestations. NF occurs usually in the extremities, perineum, abdomen, and rarely in the head and neck region. Early diagnosis, combination of intravenous antibiotics and early surgical debridement are crucial in the management of NF. We report a 74- year old woman with a rapidly progressive cervical NF following febrile neutropenia, resistant to intravenous antibiotics. We briefly comment on current management of cervical NF and the timing of debridement. We believe that this report will remind otolaryngologists to consider NF in differential diagnosis when dealing with patients who have suspicious findings.

#### Keywords

*Fasciitis; cervical; necrotizing;  
infection*

---

### ÖZET

---

Nekrotizan fasiit (NF) subkutan dokular ve fasiyal planların nekrozuna yol açan ölümcül bir yumuşak doku enfeksiyonudur. Sistemik belirtileri olabilmektedir. NF genellikle ekstremiteler, perine, abdomende ve nadir olarak da baş boyun bölgesinde ortaya çıkar. Erken tanı, kombine intravenöz antibiyotikler ve erken cerrahi debridman NF tedavisinde önemlidir. Bu çalışmada 74 yaşında bayan hastada febril nötropeniyi takiben gelişen; intravenöz antibiyotiklere dirençli hızlı ilerleyen servikal nekrotizan fasiit olgusundan bahsettik. Biz bu olgu sunumunun benzer durumla karşılaşacak baş ve boyun cerrahları için şüpheli NF bulguları olan hastaların değerlendirilmesinde uyarıcı nitelikte olduğu kanaatindeyiz.

#### Anahtar Sözcükler

*Fasiit; servikal; nekrotizan;  
enfeksiyon*

**This study has been presented in 9<sup>th</sup> International Ear, Nose, Throat, Head and Neck Congress.**

Çalışmanın Dergiye Ulaştığı Tarih: 14.03.2012

Çalışmanın Basıma Kabul Edildiği Tarih: 15.01.2013



Correspondence

Hazan BAŞAK, MD

Ankara University Medical Faculty,

Department of Otolaryngology and Head and Neck Surgery,

Ankara

hbasak@ankara.edu.tr

---

## INTRODUCTION

---

**N**ecrotizing Fasciitis (NF) is a rapidly progressive and fatal polymicrobial soft tissue infection causing necrosis of the subcutaneous tissue and fascial planes.<sup>1-3</sup> The causative agents may be aerobic, anaerobic or mixed flora.<sup>4</sup> Microorganisms spread from the subcutaneous tissue along the superficial and deep fascia planes. This infection leads to vascular occlusion, ischemia and tissue necrosis as well as systemic toxicity.<sup>5</sup>

A history of trauma or surgery to the involved area is often present. Insect bites, local ischemia, hypoxia, systemic diseases (e.g., diabetes, immunocompromised disease), alcohol or i.v drug abuse are the predisposing factors for NF.<sup>5,6</sup> It is not easy to diagnose NF in the early stage, and therefore it can progress rapidly.<sup>7,8</sup> Early diagnosis, broad spectrum antibiotics and surgical debridement are current therapy methods of cervical NF. However, despite aggressive management, the mortality is still high.<sup>5</sup> Written informed consent was obtained from the patient for publication of this case report and accompanying images.

---

## CASE REPORT

---

A 74-year old woman was referred to the emergency department with the history of 3-day fever. Physical examination was non-contributory. Blood count showed pancytopenia. The patient was hospitalized and broad spectrum intravenous antibiotics (Teicoplanin and Imipenem) were administered for febrile neutropenia in addition to i.v. fluids and nutritional support. The result of bone marrow aspiration and biopsy was suspicious for lymphoproliferative disorder. In the second day of the treatment a swelling appeared on the left side of her neck and was consulted to our department. We noticed a swelling and erythema on the left submandibular area. Furthermore, there was a gingival leukoplakia and the oral cavity hygiene was poor. USG of the neck revealed sialoadenitis. Cutaneous biopsy obtained by dermatologists showed lymphocytic infiltration as the sole finding. Blood, sputum and tissue cultures were taken. In the blood and the sputum cultures *Pseudomonas aeruginosa* and *Acinetobacter baumannii* were detected respectively. Afterwards, colistin; clindamycin and caspofungin were added to the previous regimen. The skin lesions of the neck started to enlarge and excoriate. Second cutaneous

biopsy was taken and the result was reported as pyoderma gangrenosum. Three days after the biopsy, the patient deteriorated to septic shock; therefore, prednisolone, and dopamin infusions were started. As soon as the necrosis of the neck skin was noticed, the patient was reconsulted to our department and an immediate surgical debridement was performed (Figure 1-2-3). Foul-smelling brownish exudates were aspirated. All the necrotic soft tissue (the skin and fascia) of the neck from mandible to the clavicle was dissected. Fortunately, the neck muscles were not involved. Surgical area was irrigated with large amount of rifocin and saline (Figure 4). The patient was transferred to the Intensive Care Unit (ICU) postoperatively. Intravenous immunoglobulin infusion (pentaglobulin) was administered for 3 days and the daily dressing was done with rifocin and saline. The patient's general status began to improve in the immediate postoperative period. Erythrocyte transfusions and plasma apheresis were required for 5 times. Twenty-one days after the surgery, the cervical defect was reconstructed with a cervicofacial advancement flap and a split thickness graft. The patient was discharged with a normal blood cell count and an acceptable morbidity (with limited mouth opening, ectropion and aesthetic deformity) 4 weeks after the debridement (Figure 5).

---

## DISCUSSION

---

Necrotizing Fasciitis is very rare in the head and neck region. If it occurs in this region; most common cause is the odontogenic infections and it may affect patients of all ages.<sup>8,9</sup> Most of the cases with NF have predisposing factor such as dental caries, oral trauma and surgery to involved area, burns, insect bites, systemic disease (e.g. Diabetes, arteriosclerosis, etc) alcoholism and/or malignancy.<sup>9,10</sup>

The complications of cervical NF include septic shock, jugular vein thrombosis, mediastinitis, airway obstruction and multiple organ failure.<sup>5</sup> The causative organisms are mostly oral flora members (*Peptostreptococcus* spp, *Bacteroides*, *Fusobacterium*, and *Colostridium*), *staphylococcus-streptococcus* species, and *Pseudomonas aeruginosa*. However, the infection is usually polymicrobial.<sup>8,11</sup>

The successful management of NF requires early diagnosis, combination of broad spectrum intravenous antibiotics, iv fluids, nutritional support and surgical debridement. Furthermore there are many reports regarding role of hyperbaric oxygen (HBO) therapy in NF.

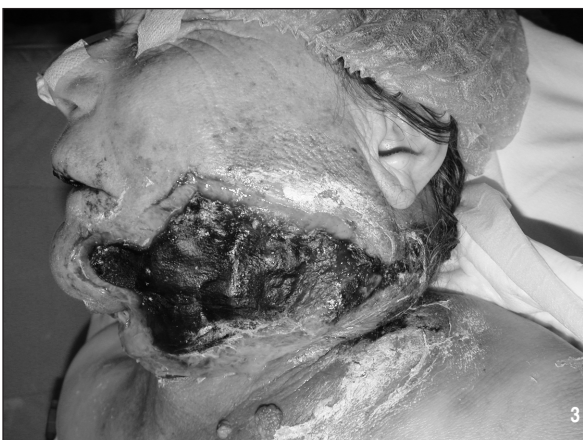
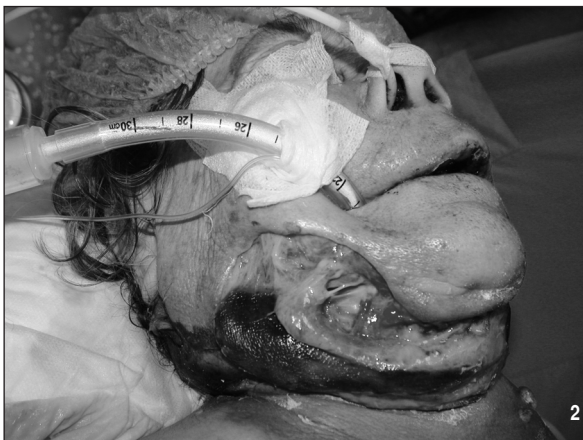
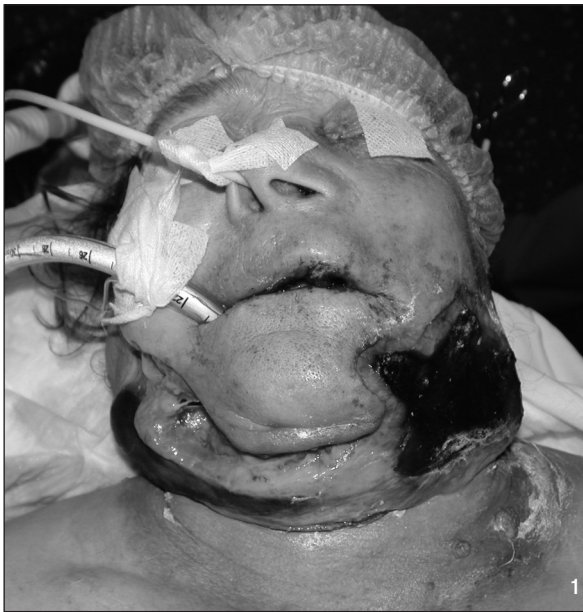Figure 1-3. Preoperative skin lesions and gangrene formation.

HBO may be used as an adjunctive therapy for NF patients who are stable in terms of general condition. However, HBO treatment is technically very difficult for a patient in ICU.<sup>12</sup> Intravenous Immunoglobulin (IVIG)

therapy might also be used in the treatment of NF in addition to intravenous antibiotics and surgical debridement because it contains antibodies capable of neutralizing bacterial antigens.<sup>13</sup> IVIG was administered to our patient but adjunctive HBO therapy was not applicable due to her poor physical condition in ICU and technical difficulties.

It is difficult to diagnose NF in early stages due to its benign appearance. In the early stage, the skin is in-

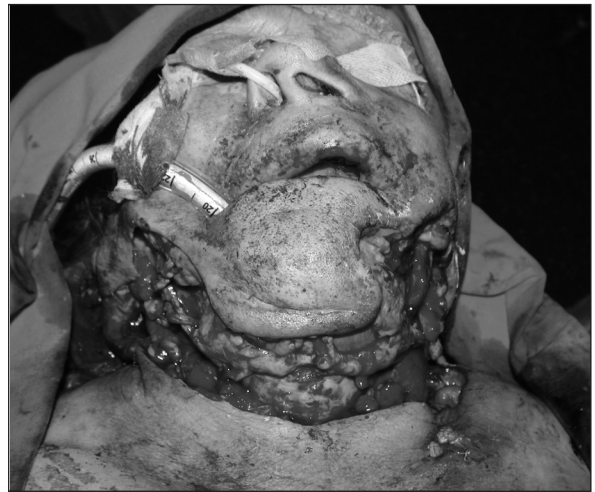

Figure 4. Surgical debridement of necrotic soft tissue.

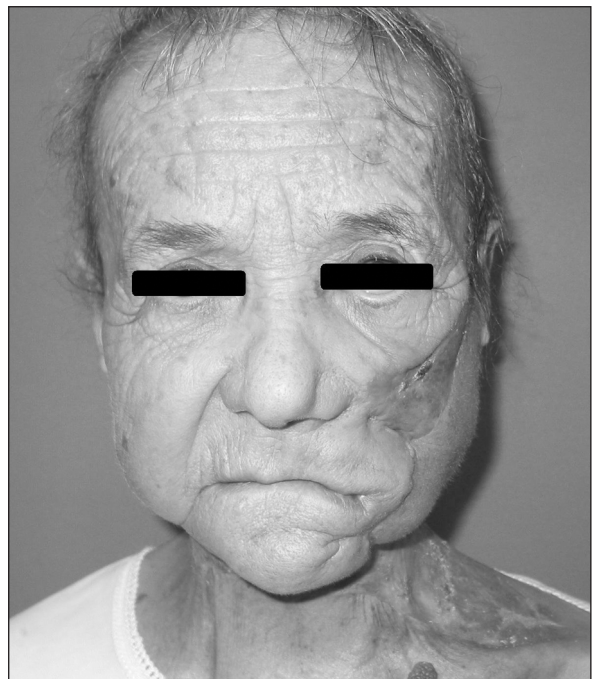


Figure 5. Five months postoperatively.

flamed and tense. After that, an erytéma begins. When the infection spreads to the deep tissue and fascial planes, the skin color starts to get bluish with irregular borders. Eventually, skin necrosis becomes evident, but it is a late sign of NF.<sup>8</sup> In our patient, the skin lesions quickly enlarged and gangrene developed; skin gangrene continued to enlarge despite the broad spectrum intravenous antibiotics. We performed an immediate surgical debridement as soon as we realized the skin necrosis. However, according to our opinion, debridement was delayed because the primary physician of the patient had waited for the result of skin biopsy;

otherwise, it would have been performed a little bit earlier.

In conclusion, cervical NF is a life threatening, aggressive infection with high morbidity and mortality. Early diagnosis, broad spectrum antibiotics and immediate surgical debridement are crucial in the management. Promising treatment methods such as HBO and IVIG may be useful when combined with surgical debridement.<sup>10,14,15</sup> We believe that, combined treatment supported with psychological therapy and appropriate reconstruction may decrease morbidity and mortality rate.

---

## REFERENCES

---

- Gallia LJ, Johnson JT, Cervical necrotizing fasciitis. *Otolaryngol Head Neck Surg* 1981;89(6):935-7.
- Kantu S, Har-El G. Cervical necrotizing fasciitis. *Ann Otol Rhinol Laryngol* 1997;106(11):965-70.
- Sudarsky LA, Lashinger JC, Coppa GF, Spencer FC. Improved results from a standardized approach in treating patient with necrotizing fasciitis. *Ann Surg* 1987;206(5): 661-5.
- Safak MA, Haberal I, Kiliç D, Göçmen H. Necrotizing fasciitis secondary to peritonsillar abscess: a new case and review of eight earlier cases. *Ear Nose Throat J* 2001;80(11): 824-30, 833.
- Adoga AS, Otene AA, Yiltok SJ, Adegwu A, Nwaorgu OG. Cervical necrotizing fasciitis: case series and review of literature. *Niger J Med* 2009;18(2):203-7.
- Reed JM, Anand VK. Odontogenic cervical necrotizing fasciitis with intrathoracic extension. *Otolaryngol Head Neck Surg* 1992;107(4):596-600.
- Wong CH, Chang HC, Pasupathy S, Khin LW, Tan JL, Low CO. Necrotizing fasciitis: clinical presentation microbiology and determinants of mortality. *J Bone Joint Surg Am* 2003;85-A(8):1454-60.
- Oğuz H, Demirci M, Arslan N, Şafak MA, Paksoy G. Necrotizing fasciitis of the head and neck: Report of two cases and literature review. *Ear Nose Throat J* 2010;89(2): E7-10.
- Bakshi J, Virk RS, Jain A, Verma M. Cervical necrotizing fasciitis: Our experience with 11 cases and our technique for surgical debridement. *Ear Nose Throat J* 2010;89(2):84-6.
- Skitarelic N, Mladina R, Morovic M, Skitarelic N. Cervical necrotizing fasciitis: sources and outcomes. *Infection* 2003; 31(1):39-44.
- De Ru JA, Leverstein-Van Hall M. Microbiology in complicated head and neck infections. *B-ENT* 2010;6(1):27-33.
- Morgan MS. Diagnosis and management of necrotising fasciitis: a multiparametric approach. *J Hosp Infect* 2010;75(4): 249-57.
- Morioka D, Nakatani K, Watanabe S, Shimizu Y, Ohkubo F, Hosaka Y. Cervical necrotizing fasciitis with upper trunk extension. *Eur J Plast Surg* 1999;22(5-6):264-66.
- Chan CH, McGurk M. Cervical necrotising fasciitis a rare complication of periodontal disease. *Br Dent J* 1997;183(8): 293-6.
- Ulubil SA, Iseri M, Ozturk M, Ustundag E, Aydin O. Cervical necrotizing fasciitis. *J Otolaryngol Head Neck Surg* 2009; 38(1):E23-8.