

Kimura's Disease of the Parotid Region With Multiple Symmetric Lipomatosis: Case Report

Parotis Bölgesinde Kimura Hastalığı ve Multiple Simetrik Lipomatozis Olgusu

Dr. Ayşe İRİZ*, Dr. Adil ERYILMAZ*, Dr. Tuba ÜNAL**, Dr. Muharrem DAĞLI*, Dr. Hakan KORKMAZ*,
Dr. Güleser SAYLAM KILIÇ*.

* Ankara Numune Hospital, Department of Otolaryngology-Head and Neck Surgery

** Ankara Numune Hospital, Department of Pathology

ABSTRACT

Kimura's disease is a rare chronic inflammatory disorder of unknown etiology, primarily seen in young and middle-aged Asian males. The disease is characterized by a triad of painless subcutaneous masses and regional lymphadenopathy in the head and neck region, blood and tissue eosinophilia, and markedly elevated serum IgE levels. Renal involvement may be seen in most Kimura's disease patients. We are presenting a 44 years- old male patient with Kimura's disease in the parotid region with renal involvement. The patient also had multiple symmetric subcutaneous lipomas of the extremities, upper neck and shoulders.

Keywords

Kimura's disease, parotid gland, Multiple symmetric lipomatosis

ÖZET

Kimura hastalığı genellikle Asya'lı genç ve orta yaşlı erkeklerde görülen, nedeni bilinmeyen, nadir kronik inflamatuvar bir hastalıktır. Genellikle baş-boyun bölgesinde ağrısız tümör benzeri subkutan kitle ve rejyonel lenfadenopati şeklinde karşımıza çıkar. Kan ve dokuda artmış eozinofili ve artmış kan IgE düzeyleri de diğer tipik bulgularıdır. Bir çok Kimura hastasında renal tutulum gelişebilir. Biz bu makalede parotis ve postauriküler bölgede Kimura hastalığı tanısı almış 44 yaşında erkek hasta sunuyoruz. Hastada aynı zamanda Kimura hastalığına bağlı renal tutulum ve ekstremitelerde, boyun ve omuzlarında multipl sistemik lipomatozis tanısı da konulmuştur.

Anahtar Kelimeler

Kimura, Parotis, Multipl Simetrik Lipomatozis

Çalışmanın yapıldığı klinik(ler): **Ankara Numune Hastanesi, 3. Kulak Burun Boğaz Kliniği**

Çalışmanın Dergiye Ulaştığı Tarih: **11.01.2005** · Çalışmanın Basıma Kabul Edildiği Tarih: **01.07.2005**

Yazışma Adresi

Dr. Muharrem DAĞLI

Cemal Gürsel Cad. No: 48/1 06600 Cebeci Ankara/Turkey

INTRODUCTION

Kimura's disease is characterized by long standing painless subcutaneous nodules in the head and neck region (3,10,11). Laboratory findings are non-specific, but most of the patients have blood and tissue eosinophilia and elevated serum immunoglobulin E levels. There is a high incidence of renal involvement and proteinuria in 12% to 16% of the cases (2,9). We are reporting a patient with Kimura's disease in the parotid region with renal involvement and multiple symmetric lipomatosis. Multiple symmetric lipomatosis (MLS) is a rare disease characterized by the growth of uncapsulated masses of adipose tissue.

We couldn't find any reported literature that presented a patient with Kimura's disease and MLS.

CASE REPORT

A 44-year-old male patient applied to our clinic with 10 years history of enlarging mass in the right preauricular region and 5 years history of a second mass in the postauricular region of the same site. The physical examination revealed a 2×2.5 cm soft, nontender and semimobile mass in the preauricular region and another mass of 1×1.5 cm in the postauricular region. There was no cervical lymph node on palpation. Multiple, subcutaneous, mobile, symmetric, soft lipoma like masses were determined on

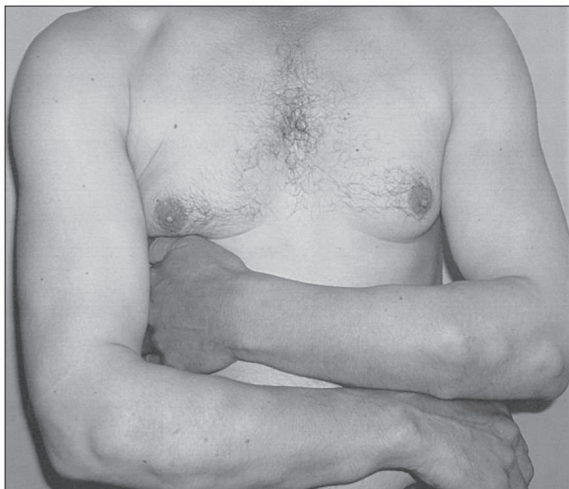

Figure 1. Multiple symmetric lipomas on the upper extremities.

the various parts of his body. These masses, ranging from 2 to 10 cm in diameter, were located mostly on the extremities, upper neck and shoulders, total number reaching to approximately 30 (Resim 1). Other physical findings were non-specific. He had also history of renal disease for 30 years. Fine needle biopsy of the kidney was reported as mesangioproliferative glomerulonephritis 5 years ago.

Laboratory findings were within normal limits except for peripheral blood eosinophilia (21.5%), serum total IgE level of 3000 IU/mL (0–100 IU/mL), proteinuria (500mg/dl) and hypercholesterolemia (250 mg/dL). Axial computerized tomograph (CT) imaging showed a 2×2 cm soft tissue mass in the right superficial parotid region and 1×1.5 cm of another mass in the postauricular re-

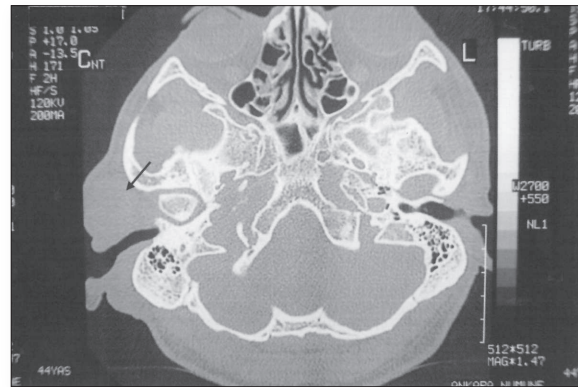


Figure 2. Axial CT scan shows 2×2 cm soft tissue mass in the right parotid region and 1×1.5 cm. of similar mass in the postauricular region.

gion (Resim 2). Fine needle aspiration biopsy of the right parotid mass was non-diagnostic. The patient underwent a right superficial parotidectomy with the excision of postauricular mass. One of the subcutaneous nodules on his arm was also excized for histopathologic examination. The description of right superficial parotidectomy material was based on the characteristic histopathologic findings and was diagnosed as Kimura's disease: Histologically; involved lymphoid tissues showed reactive prominent germinal centers containing cellular, fibrous and vascular components. The cellular component consisted of dense eosinophilic infiltrates of the interfollicular zones, lysis of follicles, and microabscesses (Resim 3, 4). The diagnosis of the lesion from the arm was reported as lipoma.

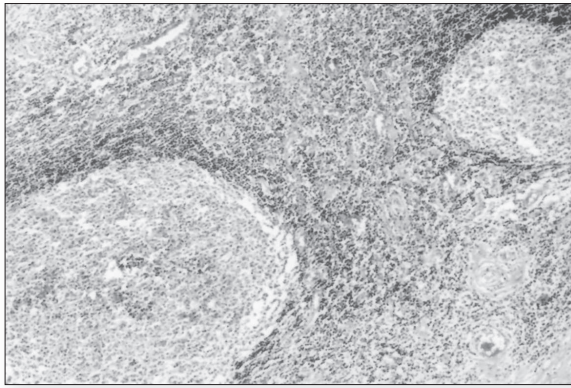


Figure 3. Prominent reactive appearing germinal centers are seen within this hyperplastic lymph node. Proliferation of venules are seen in interfollicular area. (H&E×40)

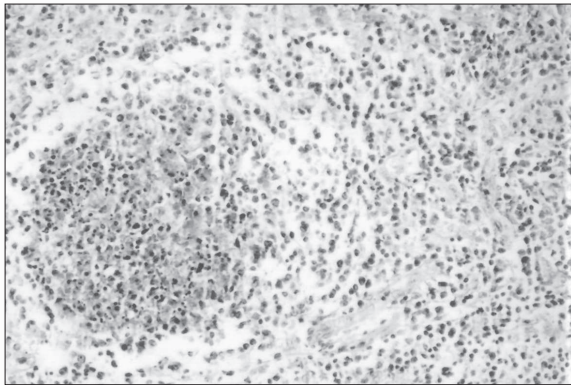


Figure 4. Eosinophilic microabscess in germinal center. (H&E×100)

DISCUSSION

Kimura's disease appeared in the literature in 1948 after a systematic description by Kimura et al (6). The disease typically presents with painless subcutaneous masses with or without lymph nodes in the head and neck region. The disease usually involves subcutaneous tissues, lymph nodes, parotid and submandibular salivary glands (1,3,10,11). Kimura's disease (KD) can be confused with angiolymphoid hyperplasia with eosinophilia, but recently has been clearly described as a separate clinico-pathological entity (9,10,11) Angiolymphoid hyperplasia with eosinophilia is a rare but distinctive vascular tumor typically presenting in women during early to mid-adult life. Lymphadenopathy is uncommon, and blo-

od eosinophilia is noted in <10% of cases. Histologically, the presence of inflammation around medium-sized arteries or veins and evidence of vascular damage are key features in differentiating angiolymphoid hyperplasia with eosinophilia from Kimura's disease (10).

Kimura's disease has an unknown etiology, and is self-limited. Allergic or autoimmune reactions may play role. It has been speculated that candida albicans, viruses, parasites or neoplasms may alter T-cell immunoregulation or induce IgE-mediated type I hypersensitivity resulting in the release of eosinophilotropic cytokines (3,10).

The general consensus is that KD is a chronic inflammatory condition.

Only 5 pediatric and 11 adult cases of Kimura's disease with renal involvement have been reported in the literature (4,9). Proteinuria was reported in 12-16% of the patients of whom 60-78% developed nephrotic syndrome (2,9,10). Various renal pathologies such as membranous nephritis, minimal change disease, mesangioproliferative glomerulonephritis, IgM or IgA mediated nephritis can be associated with KD (2,9). Drug resistant nephrotic syndrome is a rare condition in KD. The patient had nephrotic syndrome for 10 years before the diagnosis of KD. During this period, the nephrotic syndrome was aggressively treated with steroids and cytotoxic agents. The pathogenesis of KD and the associated renal involvement is not well understood. Some have proposed common etiological factors for both KD and glomerular lesions. Furthermore corticosteroid agents, known to modulate lymphokine production and T-cell proliferation, are used in the treatment of both nephrotic syndrome and KD. A defect in T-cell immunoregulation may play a role in the pathogenesis of both entities (9).

Multiple (Benign) symmetric lipomatosis (MSL) is an inherited disorder in which enlarging and encapsulated lipomas symmetrically develop in the subcutaneous tissue. Type 1 benign symmetric lipomatosis affects primarily men and is characterized by fat accumulation around the neck, nape of the neck, upper back, shoulders, and upper arms. Type 2 affects both men and women and is characterized by an exaggerated female fat distribution in the upper back, deltoid, upper arms, hips, and upper thigh region. Unlike lipomas the lesions are noncapsulated (8). The pathogenesis of MSL is completely un-

nown. In some cases, it is associated with mitochondrial DNA abnormalities (7). Rarely, hypercholesterolemia can be seen with MLS. Our patient had hypercholesterolemia with subcutaneous multiple, symmetric lipomatosis on the arms, upper back, shoulders and thigh region. This is the first patient with both Kimura's disease and multiple symmetric lipomatosis reported in the literature. However, literature review presents no etiological and pathophysiological association between these entities.

The diagnosis of KD is often difficult. Patients with Kimura's disease should be often extensively evaluated for other serious disorders and neoplasia. Radiologic imaging can not diagnose these diseases accurately (10). Biopsy is important to exclude malignant disorders. Fine-needle aspiration biopsy of the mass is nondiagnostic (3,5,10,11). A lot of patients with Kimura's disease had undergone surgery

because the diagnosis was difficult without making biopsy (1,10). The histopathology of Kimura's disease is characterized, by prominent germinal centers in involved lymph nodes containing cellular, vascular and fibrous components. The cellular component consists of dense eosinophilic infiltrates in a background of abundant lymphocytes and plasma cells, eosinophilic microabscesses with central necrosis, Warthin-Finkeldey-type polykaryocytes (3,10).

The treatment of Kimura's disease is not well formulated; malignant transformation has not been reported (3). Surgical excision is the most common diagnostic measure and is often also therapeutic. Ablative surgery should be avoided. Other therapeutic options include radiation, systemic steroids and various cytotoxic agents. Recurrence is common (1). On the physical examination of the patient there was no recurrence in three years follow up.

REFERENCES

1. Armstrong WB, Allison G, Pena F, Kim JK. Kimura's disease: two case reports and a literature review. *Ann Otol Rhino Laryngol* 107:1066–1071, 1998.
2. Atar S, Oberman AS, Ben-Izhak O, Flatau E. Recurrent nephrotic syndrome associated with Kimura's disease in a young non-oriental male. *Nephron* 68:259–261, 1994.
3. Chan KM, Mok JSW, Victor A. Kimura's disease of the auricle. *Otolaryngol Head Neck Surg* 124:598–599, 2001.
4. Chartapisak W, Opastrakul S. Steroid-resistant nephrotic syndrome associated with Kimura's disease. *Am J Nephrol* 22 (4):381–384, 2002.
5. Chow TCL, Yuen RWS, Tsui WMS, Ma TKE, Chow WH, Chan SK. Cytologic-features of Kimura's disease in fine-needle aspirates. *Am J Clin Pathol* 102:316–321, 1994.
6. Kimura T, Yoshimura S, Ishimura E. Unusual granulation combined with hyperplastic changes of lymphatic tissue. *Trans Soc Pathol Jpn* 37:179–18, 1948.
7. Nielsen S, Levine J, Clay R, Djensen M. Adipose tissue metabolism in benign symmetric lipomatosis. *J Clin Endocr and Metabol* 86:2717–2720, 2001.
8. Nisoli E, Regianini L, Briscini L, Bulbarelli A, Busetto L, Coin A, et al. Multiple symmetric lipomatosis may be the consequence of defective noradrenergic modulation of proliferation and differentiation of brown fat cells. *J Pathol* 198:378–387, 2002.
9. Rajpoot DK, Pahl M, Clark J. Nephrotic syndrome associated with kimura disease. *Pediatr Nephrol* 14:486–488, 2000.
10. Shetty AK, Beaty MW, Mcguirt WF, Woods CR, Givner LB. Kimura's Disease: A Diagnostic Challenge. *Pediatr* 110 (3):39, 2002.
11. Taşkin M, Gokaslan T, Kanani R, daSilva M. Patologic quiz case1. *Arch Otolaryngol Head Neck Surg* 122:892–895, 1996.