

Effect of a Combination of Bromelain and Arnica on Periorbital Edema and Ecchymosis in Septorhinoplasty

Arnika ve Bromelain Kombinasyonunun Septorinoplastide Periorbital Ödem ve Ekimoza Etkisi

¹ Yavuz Sultan Selim YILDIRIM^a, ² Emrah GÜLMEZ^a, ³ Öner SAKALLIOĞLU^a, ⁴ Hasan ÇETİNER^a,
⁵ Sertaç DÜZER^a, ⁶ Nihat SUSAMAN^a

^aClinic of Otorhinolaryngology, Elazığ Fethi Sekin City Hospital, Elazığ, Türkiye

ABSTRACT Objective: Edema and ecchymosis seen after rhinoplasty, although it is a condition that develops in the natural course of the surgery, disturbs patients. To minimize this discomfort, the effects of different surgical techniques, surgical instruments and different drugs on edema and ecchymosis in rhinoplasty have been investigated. The aim of our study was to investigate the effect of bromelain-arnica combination gel on periorbital edema and ecchymosis after open septorhinoplasty (oSRP). **Material and Methods:** Sixty patients who underwent oSRP with osteotomies were included in the study. These patients were allocated into two groups: 30 patients who underwent oSRP were assigned as the control group (Group 1) and 30 patients who were treated with topical bromelain-arnica gel after oSRP were assigned as Group 2. Scoring of eyelid edema and periorbital ecchymosis were evaluated on the first, third, and seventh postoperative days using a scale of 0-4 as described by Kara and Gökalan. **Results:** We observed that postoperative topical bromelain-arnica gel application was clinically and statistically effective in reducing both edema and ecchymosis score in oSRP. Patients in Group 2 (arnica-bromelain group) had significantly lower periorbital edema and ecchymosis scores on postoperative days 3 and 7 compared to the control group ($p<0.05$). **Conclusion:** The results of this study support that topical application of a combination of bromelain and arnica gel provides a clinically and statistically significant reduction in periorbital edema and ecchymosis after oSRP. Use of this gel can increase patient comfort in the early postoperative period after rhinoplasty.

ÖZET Amaç: Rinoplasti sonrası görülen ödem ve ekimoz her ne kadar ameliyatın doğal seyri içinde gelişen bir durum olsa da hastaları rahatsız etmektedir. Bu rahatsızlığı en aza indirmek amacıyla rinoplastide farklı cerrahi tekniklerin, cerrahi aletlerin ve farklı ilaçların ödem ve ekimoz üzerine etkileri araştırılmıştır. Bu çalışmanın amacı, açık septorinoplasti [open septorhinoplasty (oSRP)] sonrası görülen periorbital ödem ve ekimoz üzerine bromelain-arnika jel kombinasyonunun etkisini araştırmaktır. **Gereç ve Yöntemler:** Osteotomiler ile birlikte oSRP yapılan 60 hasta çalışmaya dâhil edildi. Bu hastalar iki gruba ayrılmıştır: açık rinoplasti uygulanan 30 hasta kontrol grubu (Grup 1) ve açık rinoplasti sonrası sonrası topikal bromelain-arnika jel ile tedavi edilen 30 hasta Grup 2 olarak belirlenmiştir. Göz kapağı ödemi ve periorbital ekimozun skorlaması ameliyat sonrası 1, 3 ve 7. günlerde Kara ve Gökalan tarafından tanımlanan ve gözlemciler tarafından kullanılan 0-4 arası skala kullanılarak değerlendirildi. **Bulgular:** Ameliyat sonrası topikal bromelain-arnika jel uygulamasının oSRP'de hem ödem hem de ekimoz skorunu azaltmada klinik ve istatistiksel olarak etkili olduğunu gözlemledik. Grup 2'deki hastalarda (arnika-bromelain grubu) postoperatif 3 ve 7. günlerde periorbital ödem ve ekimoz skorları kontrol grubuna kıyasla anlamlı derecede düşüktü ($p<0.05$). **Sonuç:** Bu çalışmada elde ettiğimiz sonuçlar, bromelain ve arnika jel kombinasyonunun topikal uygulamasının oSRP sonrası periorbital ödem ve ekimozda hem klinik hem de istatistiksel olarak anlamlı bir azalma sağladığını desteklemektedir ve bunun rinoplasti hastalarında erken postoperatif dönemde hasta konforunu artıracak önemli bir sonuç olduğunu düşünürüz.

Keywords: Septorhinoplasty; edema; ecchymosis; arnica; bromelains

Anahtar Kelimeler: Septorinoplasti; ödem; ekimoz; arnika; bromelain

TO CITE THIS ARTICLE:

Yıldırım YSS, Gülmez E, Sakallıoğlu Ö, Çetiner H, Düzer S, Susaman N. Effect of a Combination of Bromelain and Arnica on Periorbital Edema and Ecchymosis in Septorhinoplasty. Journal of Ear Nose Throat and Head Neck Surgery, 2024;32(1):37-44.

Correspondence: Yavuz Sultan Selim YILDIRIM

Clinic of Otorhinolaryngology, Elazığ Fethi Sekin City Hospital, Elazığ, Türkiye

E-mail: yssyildirim@hotmail.com

Peer review under responsibility of Journal of Ear Nose Throat and Head Neck Surgery.

Received: 23 Sep 2023

Received in revised form: 03 Dec 2023

Accepted: 04 Dec 2023

Available online: 08 Dec 2023

1307-7384 / Copyright © 2024 Turkey Association of Society of Ear Nose Throat and Head Neck Surgery. Production and hosting by Türkiye Klinikleri.

This is an open access article under the CC BY-NC-ND license (<https://creativecommons.org/licenses/by-nc-nd/4.0/>).



Septorhinoplasty is a common procedure carried out in the ear-nose-throat clinics. Standard septorhinoplasty osteotomies can cause significant periorbital edema and ecchymosis. These usually result from injury to the vessels passing through the osteotomy areas and broken nasal bones and may lead to a significant increase in morbidity. Accordingly, rapid recovery is of prime importance for patients undergoing septorhinoplasty. Although edema and ecchymosis can be minimized with careful surgical techniques, they cannot be prevented completely.^{1,2}

Arnica is a genus of herbaceous plants native to Europe and the mountains of Western North America that has gained increasing popularity in complementary and alternative medicine. Arnica plays a key role in reducing edema, ecchymosis, and pain via its hematopoietic properties, although the exact mechanism of action remains elusive. Various theories have been proposed, among which one theory posits that arnica reduces the release of histamine from mast cells while another theory proposes that arnica reduces the expression of proinflammatory cytokines.³⁻¹²

Bromelain is a mixture of protease enzymes derived from the stems of pineapples and is primarily used for its anti edema, antithrombotic, and fibrinolytic properties.^{3,13} Several studies have reported the beneficial effects of bromelain on edema, ecchymosis, and pain as well. Although the exact mechanism of bromelain is not fully elucidated, it is known to inhibit NF- κ B. *In vitro* studies have shown that bromelain can decrease the levels of prostaglandin E2, thromboxane B2, and interleukin-8. Moreover, bromelain can increase blood flow to and oxygenation of the injured area.^{3,14-20}

The current study was designed to investigate the effect of a combination of topical bromelain and arnica gels on periorbital edema and ecchymosis following septorhinoplasty, which to our knowledge, has not been reported in the literature.

MATERIAL AND METHODS

Sixty patients who underwent open septorhinoplasty (oSRP) with osteotomies were recruited to the study.

The age of the patients ranged from 21 to 42 years; 34 of the patients were female and 26 were male. The study was conducted in accordance with the Declaration of Helsinki and was approved by the Firat University Non-invasive Research Ethics Committee (date: October 15, 2020, no: 2020/14-15). All patients were provided details about the study and written informed consent was obtained from each participant.

Sixty patients were divided into two groups: Group 1 consisted of 30 patients who underwent oSRP and were assigned as controls while Group 2 consisted of 30 patients who were treated with topical bromelain-arnica gel after oSRP. The bromelain-arnica gel was applied topically three times in a day to the ecchymosis and edema around the eyes of each patient from postoperative day 1 to day 7.

Patients with diabetes mellitus, hypertension, peptic ulcer, psychiatric disorders, known allergy to any drug, use of anticoagulant therapy 5 days prior to the surgery, hematologic disorders and fibrinolytic disorders were excluded from the study. Patients in both groups had complaints of nasal obstruction and were diagnosed with nasal septal deviation by means of anterior rhinoscopy and endoscopic nasal examination by the first and second authors of the current study. We avoided carrying out the surgery on female patients during or immediately before their menstrual period.

The oSRP surgery with dorsal hump extraction and medial and lateral osteotomies was carried out under intubation and general anesthesia for all patients. After the removal of the dorsal hump, guided and curved 4-mm lateral osteotomies were used. The lateral osteotomies were carried out bilaterally without subperiosteal elevation and endonasally by performing a small incision at the pyriform aperture just above the level of the anterior end of the inferior turbinate in all patients. Each surgeon operated on an equal number of patients in each group. During the operation, the mean arterial blood pressure was maintained at 70 to 90 mmHg with the infusion of esmolol.

After completing the oSRP surgery, antibiotic soaked nonabsorbable packs (Merocel, Medtronic

Xomed Inc. USA) were placed into the nose bilaterally. External nasal cast splints were routinely used for all patients. During the first postoperative 24 hours, the patients were asked to lie down at a 45 degrees elevated position of their head and ice packs were applied. The nonabsorbable packs were removed on the second postoperative day for all patients. The patients were prescribed the same antibiotic (amoxicillin 1 g bid for 10 days) and the same analgesic (paracetamol quid for 10 days).

Scoring of eyelid edema and periorbital ecchymosis was carried out on the 1st, 3rd, and 7th postoperative days using scale of 0 to 4 as described previously by Kara and Gökalan (Figure 1, Figure 2).¹

IBM SPSS Statistics 21 was used for all statistical analyses. One-way analysis of variance (ANOVA) or the Kruskal-Wallis test was used to compare variables between the groups. $p < 0.05$ was considered as statistically significant.

RESULTS

A total of 60 patients (34 female and 26 male) between the age of 21 and 42 years (mean age \pm SD, 29 \pm 9 years) who underwent oSRP with osteotomies were included in the study. Of these, 30 patients (12 male and 18 female) were assigned as controls (age 21-39 years, mean age \pm SD, 28 \pm 7 years,) while the remaining 30 patients (14 male and 16 female) who were treated with the bromelain-arnica gel were assigned as the study group (age 21-42 years, mean age \pm SD, 27 \pm 8 years). No statistically significant differences in age and gender were identified between the groups.

The postoperative edema and ecchymosis scores with and without the application of topical bromelain-arnica gel are showed graphically in Figure 3, Figure 4 and Table 1, Table 2, Table 3, Table 4. Administration of topical bromelain-arnica gel after oSRP surgery was clinically effective and could significantly decrease the score of both edema and ecchymosis ($p < 0.05$) compared to the control group on postoperative 3rd and 7th days. We did not observe any complications associated with

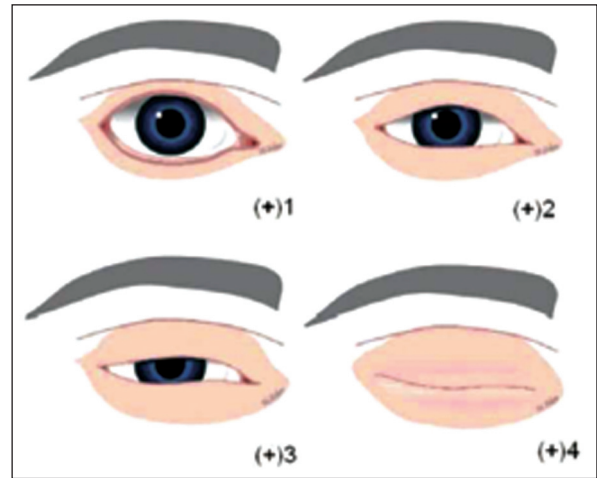


FIGURE 1: Grading scale for periorbital edema. 0: none. (+) 1, minimal. (+) 2, extending on to the iris. (+) 3, covering the iris. (+) 4, massive edema.

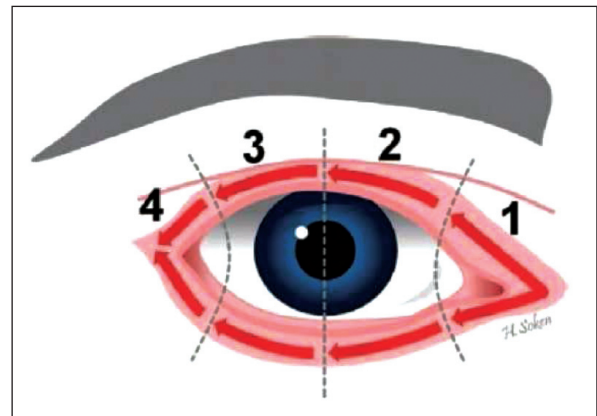


FIGURE 2: Grading scale for periorbital ecchymosis. (+) 1, extending to the medial canthus. (+) 2, extending to the pupil. (+) 3, past the pupil. (+) 4, extending on to the lateral canthus.

the use of topical bromelain-arnica gel or oSRP surgical procedure.

DISCUSSION

Septorhinoplasty is an effective cosmetic surgery that is widely carried out world-wide. Complications involving skin and soft tissues may occur during the procedure due to the force applied to reshape the nose. These complications can significantly affect patient satisfaction.²¹⁻²³ In particular, complications such as edema and ecchymosis can be distressing for the patients in the early postoperative period. Of note, edema in the first postoperative 24 hours may affect

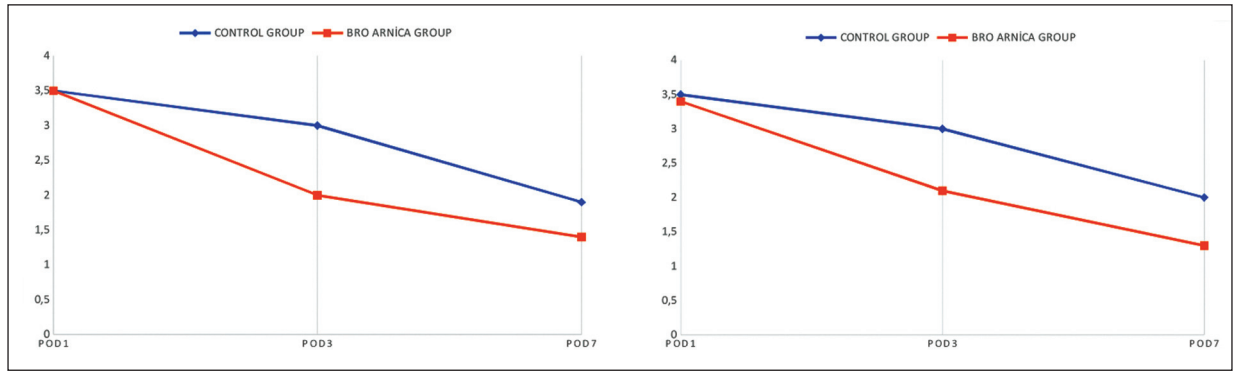


FIGURE 3: a) Mean ecchymosis scores of upper eyelids. The X axis represents the POD 1, 3 and 7. The Y axis represents a score between 0 and 4. b) Mean ecchymosis scores of lower eyelids. The X axis represents the postoperative day (POD) 1, 3 and 7. The Y axis represents a score between 0 and 4.

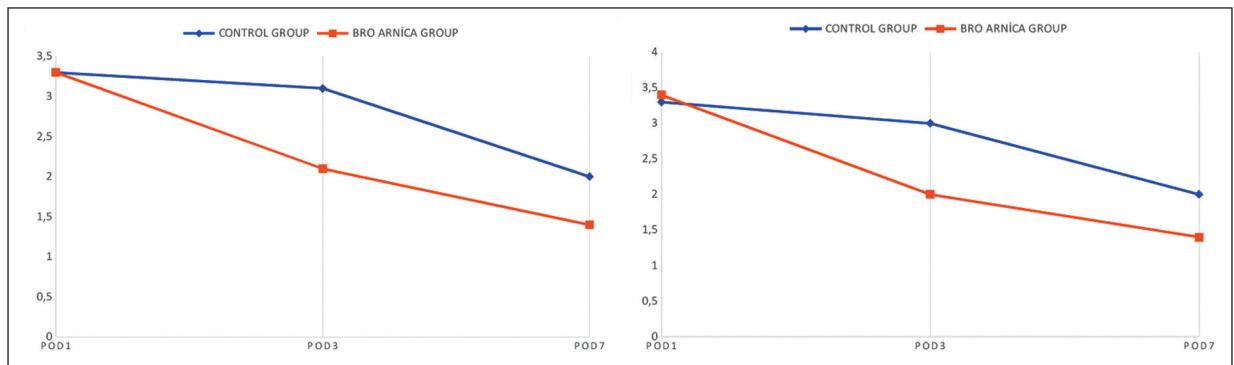


FIGURE 4: a) Mean edema scores of upper eyelids. The X axis represents the POD 1, 3 and 7. The Y axis represents a score between 0 and 4. b) Mean edema scores of lower eyelids. The X axis represents the postoperative day (POD) 1, 3 and 7. The Y axis represents a score between 0 and 4.

TABLE 1: Mean ecchymosis scores of upper eyelids. POD, indicates postoperative day. The X axis represents the POD 1, 3 and 7. The Y axis represents a score between 0 and 4.

	Control group	Arnica+Bromelain group	p value
POD 1	3.366	3.333	0.816
POD 3	3.166	2.166	0.019
POD 7	2.033	1.433	0.017

POD: Postoperative day.

TABLE 3: Mean edema scores of upper eyelids. The X axis represents the POD 1, 3 and 7. The Y axis represents a score between 0 and 4.

	Control group	Arnica+Bromelain group	p value
POD 1	3.566	3.533	0.797
POD 3	3.033	2.000	0.001
POD 7	1.966	1.400	0.006

POD: Postoperative day.

TABLE 2: Mean ecchymosis scores of lower eyelids. The X axis represents the POD 1, 3 and 7. The Y axis represents a score between 0 and 4.

	Control group	Arnica+Bromelain group	p value
POD 1	3.333	3.466	0.0515
POD 3	3.066	2.033	0.015
POD 7	2.066	1.466	0.003

POD: Postoperative day.

TABLE 4: Mean edema scores of lower eyelids. The X axis represents the POD 1, 3 and 7. The Y axis represents a score between 0 and 4.

	Control group	Arnica+Bromelain group	p value
POD 1	3.533	3.466	0.709
POD 3	3.000	2.100	0.019
POD 7	2.000	1.366	0.002

POD: Postoperative day.

visual acuity while ecchymosis may lead to disruptions in the patients' social activities due to increased pigmentation.²⁴ Although over the years numerous techniques have been developed to reduce edema and ecchymosis, post-rhinoplasty care remains a contentious issue.^{25,26} Since rhinoplasty remains a demanding and popular surgery, it is important to ensure that clinicians follow best practices to reduce morbidity.^{26,27} To the best of our knowledge, this is the first study in the literature to investigate the effect of a combination of topical bromelain and arnica gel on periorbital edema and ecchymosis following septorhinoplasty.

A previous study has reported the effect of arnica bromelain combination on ecchymosis after blepharoplasty. A total of 130 patients received the tablet forms of arnica and bromelain for a total of two weeks, one week before surgery and another week after surgery, while the control group received no treatment. The authors reported no significant difference in ecchymosis between the two groups.²⁸ Different from the published study, we applied the bromelain-arnica combination gel topically on the ecchymosis and edema around the eyes of the patient, and observed a significant decrease in both ecchymosis and edema scores.

The effect of topical application of arnica and mucopolysaccharide polysulphate on periorbital edema and ecchymosis has previously been examined after open rhinoplasty.²⁹ In the referred study, the patients were divided into three groups: Group I received postoperative arnica cream treatment, Group II received postoperative mucopolysaccharide polysulphate cream treatment, and Group III (control group) received no postoperative treatment. The authors reported significant differences in periorbital edema and ecchymosis between groups I and II and the control group. No significant difference was observed between groups I and II. The authors proposed that a rapid regression of edema and ecchymosis could be achieved by local treatments with arnica and mucopolysaccharide polysulphate cream.²⁹

Sakallioğlu et al. examined the effect of tranexamic acid and methylprednisolone on periorbital

edema and ecchymosis in patients that underwent oSRP. The authors divided patients into three groups: Group I (control group) received no postoperative treatment, Group II received oral tranexamic acid, and Group III received intravenous methylprednisolone therapy. Groups II and III showed significantly lower periorbital edema and ecchymosis scores compared to the control group, while no significant difference was found between groups II and III.³⁰ A prospective, randomized triple-blinded study examined the effects of intravenous application of dexamethasone and tranexamic acid on post-rhinoplasty periorbital edema and ecchymosis. In this study, the patients were divided into four groups: Group D received dexamethasone, Group T received tranexamic acid, Group DT received dexamethasone and tranexamic acid, and Group P (control group) received no medication. The authors reported that periorbital edema and ecchymosis scores were significantly lower in the D, T, and DT groups compared to the control group, whereas no significant difference was identified between the D, T, and DT groups.³¹ Totonchi and Guyuron investigated the effect of steroids and arnica following rhinoplasty.³² These authors divided the patients into three groups: Group P received steroids, Group A received arnica, and Group C (control group) received no medication. The results indicated that both steroids and arnica could be effective in reducing edema during the early postoperative period.³²

Several published studies indicate that preoperative administration of steroids could be a preventive measure to reduce edema and ecchymosis in rhinoplasty.^{1,33,34} A meta-analysis reported that perioperative administration of repeated doses of steroids was more effective in reducing periorbital edema and ecchymosis than single-dose steroid administration.³⁵ Combined use of lidocaine and adrenaline was shown to reduce intraoperative bleeding and postoperative pain in patients undergoing rhinoplasty although it was not as effective in reducing postoperative edema and ecchymosis.³⁶

A prospective randomized controlled double-blinded study which reported that perioperative use of

arnica montana could lead to a significant reduction in post-rhinoplasty ecchymosis compared to the control group.³⁷ Kara et al. reported that the subperiosteal tunnel created before lateral osteotomy could cause a significant increase in periorbital ecchymosis; subconjunctival ecchymosis was also increased, although the difference did not reach statistical significance. Based on these findings, the authors recommended that the creation of a subperiosteal tunnel before lateral osteotomy should be avoided.³⁸ Sakallioğlu et al. compared the effect of open and closed septorhinoplasty procedures on periorbital edema and ecchymosis and found no significant differences in the outcomes with the two techniques.³⁹ Kelleş et al. reported that the use of local heparinoids following rhinoplasty had no significant effect in preventing periorbital edema and ecchymosis.⁴⁰ A recent systematic review indicated that favorable outcomes in edema, ecchymosis, and pain control could be obtained with arnica and bromelain not only with rhinoplasty but also with orthopedic surgeries.⁴¹

CONCLUSIONS

Septorhinoplasty remains highly popular and the number of patients undergoing this procedure is growing worldwide. Periorbital edema and ecchymosis following septorhinoplasty can cause a significant increase in morbidity and a significant decrease in patient satisfaction. Several measures have been suggested to mitigate periorbital edema and ecchymosis; nonetheless, post-rhinoplasty care can still be improved. In the current randomized

control study, we investigated the efficacy of topical administration of bromelain and arnica combination gel in the reduction of periorbital edema and ecchymosis following septorhinoplasty, and we compared the results with a control group. We observed that topical administration of bromelain and arnica combination gel could lead to a significant reduction in periorbital edema and ecchymosis following septorhinoplasty.

Source of Finance

During this study, no financial or spiritual support was received neither from any pharmaceutical company that has a direct connection with the research subject, nor from a company that provides or produces medical instruments and materials which may negatively affect the evaluation process of this study.

Conflict of Interest

No conflicts of interest between the authors and / or family members of the scientific and medical committee members or members of the potential conflicts of interest, counseling, expertise, working conditions, share holding and similar situations in any firm.

Authorship Contributions

Idea/Concept: Yavuz Sultan Selim Yıldırım, Emrah Gülmez, Öner Sakallioğlu, Sertaç Düzer; **Design:** Yavuz Sultan Selim Yıldırım, Emrah Gülmez, Öner Sakallioğlu, Hasan Çetiner; **Control/Supervision:** Sertaç Düzer, Hasan Çetiner, Öner Sakallioğlu; **Data Collection and/or Processing:** Yavuz Sultan Selim Yıldırım, Emrah Gülmez; Hasan Çetiner; **Analysis and/or Interpretation:** Öner Sakallioğlu, Hasan Çetiner, Yavuz Sultan Selim Yıldırım, Sertaç Düzer; **Literature Review:** Emrah Gülmez, Hasan Çetiner, Sertaç Düzer; **Writing the Article:** Yavuz Sultan Selim Yıldırım, Öner Sakallioğlu, Emrah Gülmez; **Critical Review:** Öner Sakallioğlu, Nihat Susaman.

REFERENCES

- Kara CO, Gökalan I. Effects of single-dose steroid usage on edema, ecchymosis, and intraoperative bleeding in rhinoplasty. *Plast Reconstr Surg.* 1999;104(7):2213-8. [Crossref] [PubMed]
- Gersema L, Baker K. Use of corticosteroids in oral surgery. *J Oral Maxillofac Surg.* 1992;50(3):270-7. [Crossref] [PubMed]
- Ho D, Jagdeo J, Waldorf HA. Is there a role for arnica and bromelain in prevention of post-procedure ecchymosis or edema? A systematic review of the literature. *Dermatol Surg.* 2016;42(4):445-63. [Crossref] [PubMed]
- Kouzi SA, Nuzum DS. Arnica for bruising and swelling. *Am J Health Syst Pharm.* 2007;64(23):2434-43. [Crossref] [PubMed]
- Lyss G, Schmidt TJ, Merfort I, Pahl HL. Helenalin, an anti-inflammatory sesquiterpene lactone from Arnica, selectively inhibits transcription factor NF-kappaB. *Biol Chem.* 1997;378(9):951-61. [Crossref] [PubMed]
- Bedi MK, Shenefelt PD. Herbal therapy in dermatology. *Arch Dermatol.* 2002;138(2):232-42. [Crossref] [PubMed]
- Verma N, Tripathi SK, Sahu D, Das HR, Das RH. Evaluation of inhibitory activities of plant extracts on production of LPS-stimulated pro-inflammatory mediators in J774 murine macrophages. *Mol Cell Biochem.* 2010;336(1-2):127-35. [Crossref] [PubMed]
- Kotlus BS, Heringer DM, Dryden RM. Evaluation of homeopathic Arnica montana for ecchymosis after upper blepharoplasty: a placebo-controlled, randomized, double-blind study. *Ophthalmic Plast Reconstr Surg.* 2010;26(6):395-7. [Crossref] [PubMed]
- Robertson A, Suryanarayanan R, Banerjee A. Homeopathic Arnica montana for post-tonsillectomy analgesia: a randomised placebo control trial. *Homeopathy.* 2007;96(1):17-21. [Crossref] [PubMed]
- Jeffrey SL, Belcher HJ. Use of Arnica to relieve pain after carpal-tunnel release surgery. *Altern Ther Health Med.* 2002;8(2):66-8. [PubMed]
- Kang JY, Tran KD, Seiff SR, Mack WP, Lee WW. Assessing the effectiveness of arnica montana and rhododendron tomentosum (*Ledum palustre*) in the reduction of ecchymosis and edema after oculo-facial surgery: preliminary results. *Ophthalmic Plast Reconstr Surg.* 2017;33(1):47-52. Erratum in: *Ophthalmic Plast Reconstr Surg.* 2018;34(2):188. [Crossref] [PubMed]
- Hart O, Mullee MA, Lewith G, Miller J. Double-blind, placebo-controlled, randomized clinical trial of homeopathic arnica C30 for pain and infection after total abdominal hysterectomy. *J R Soc Med.* 1997;90(2):73-8. [Crossref] [PubMed] [PMC]
- Reider N, Komericki P, Hausen BM, Fritsch P, Aberer W. The seamy side of natural medicines: contact sensitization to arnica (*Arnica montana* L.) and marigold (*Calendula officinalis* L.). *Contact Dermatit.* 2001;45(5):269-72. [Crossref] [PubMed]
- Maurer HR. Bromelain: biochemistry, pharmacology and medical use. *Cell Mol Life Sci.* 2001;58(9):1234-45. [Crossref] [PubMed]
- Bhui K, Prasad S, George J, Shukla Y. Bromelain inhibits COX-2 expression by blocking the activation of MAPK regulated NF-kappa B against skin tumor-initiation triggering mitochondrial death pathway. *Cancer Lett.* 2009;282(2):167-76. Erratum in: *Cancer Lett.* 2020;480:48. [Crossref] [PubMed]
- Wu SY, Hu W, Zhang B, Liu S, Wang JM, Wang AM. Bromelain ameliorates the wound microenvironment and improves the healing of firearm wounds. *J Surg Res.* 2012;176(2):503-9. [Crossref] [PubMed]
- Isola G, Matarese M, Ramaglia L, Iorio-Siciliano V, Cordasco G, Matarese G. Efficacy of a drug composed of herbal extracts on postoperative discomfort after surgical removal of impacted mandibular third molar: a randomized, triple-blind, controlled clinical trial. *Clin Oral Investig.* 2019;23(5):2443-53. [Crossref] [PubMed]
- Ghensi P, Cucchi A, Creminelli L, Tomasi C, Zavan B, Maiorana C. Effect of oral administration of bromelain on postoperative discomfort after third molar surgery. *J Craniofac Surg.* 2017;28(2):e191-e7. [Crossref] [PubMed]
- Singh T, More V, Fatima U, Karpe T, Aleem MA, Prameela J. Effect of proteolytic enzyme bromelain on pain and swelling after removal of third molars. *J Int Soc Prev Community Dent.* 2016;6(Suppl 3):S197-S204. [Crossref] [PubMed] [PMC]
- Bormann KH, Weber K, Kloppenburg H, Staude P, Koch A, Meiser P, et al. Perioperative bromelain therapy after wisdom teeth extraction - a randomized, placebo-controlled, double-blinded, three-armed, cross-over dose-finding study. *Phytother Res.* 2016;30(12):2012-9. Erratum in: *Phytother Res.* 2017;31(3):516. [Crossref] [PubMed]
- Coroneos CJ, Voineskos SH, Cook DJ, Farrokyar F, Thoma A. Perioperative corticosteroids reduce short-term edema and ecchymosis in rhinoplasty: a meta-analysis. *Aesthet Surg J.* 2016;36(2):136-46. Erratum in: *Aesthet Surg J.* 2018;38(4):461. [Crossref] [PubMed] [PMC]
- Koc S, Gürbüzler L, Yaman H, Eyibilen A, Süren M, Kaya Z, et al. The effectiveness of steroids for edema, ecchymosis, and intraoperative bleeding in rhinoplasty. *Am J Rhinol Allergy.* 2011;25(2):e95-8. [Crossref] [PubMed]
- Saedi B, Sadeghi M, Fekri K. Comparison of the effect of corticosteroid therapy and decongestant on reducing rhinoplasty edema. *Am J Rhinol Allergy.* 2011;25(4):e141-4. [Crossref] [PubMed]
- Taskin U, Yigit O, Bilici S, Kuvat SV, Sisman AS, Celebi S. Efficacy of the combination of intraoperative cold saline-soaked gauze compression and corticosteroids on rhinoplasty morbidity. *Otolaryngol Head Neck Surg.* 2011;144(5):698-702. [Crossref] [PubMed]
- Ong AA, Farhood Z, Kyle AR, Patel KG. Interventions to decrease postoperative edema and ecchymosis after rhinoplasty: a systematic review of the literature. *Plast Reconstr Surg.* 2016;137(5):1448-62. [Crossref] [PubMed]
- Kelley BP, Koshy J, Hatfe D, Hollier LH Jr, Stal S. Packing and postoperative rhinoplasty management: a survey report. *Aesthet Surg J.* 2011;31(2):184-9. [Crossref] [PubMed]
- Lee HS, Yoon HY, Kim IH, Hwang SH. The effectiveness of postoperative intervention in patients after rhinoplasty: a meta-analysis. *Eur Arch Otorhinolaryngol.* 2017;274(7):2685-94. [Crossref] [PubMed]
- Seamont D, Vrocek I, Nakra T, Mancini R. Arnica and bromelain for blepharoplasty-associated ecchymosis. *The American Journal of Cosmetic Surgery.* 2018;35(3):130-4. [Crossref]
- Simsek G, Sari E, Kilic R, Bayar Muluk N. Topical application of arnica and mucopolysaccharide polysulfate attenuates periorbital edema and ecchymosis in open rhinoplasty: a randomized controlled clinical study. *Plast Reconstr Surg.* 2016;137(3):530e-535e. [Crossref] [PubMed]
- Sakallioğlu Ö, Polat C, Soylu E, Düzer S, Orhan İ, Akyiğit A. The efficacy of tranexamic acid and corticosteroid on edema and ecchymosis in septorhinoplasty. *Ann Plast Surg.* 2015;74(4):392-6. [Crossref] [PubMed]
- Mehdizadeh M, Ghassemi A, Khakzad M, Mir M, Nekooresh L, Moghadamnia A, et al. Comparison of the effect of dexamethasone and tranexamic acid, separately or in combination on post-rhinoplasty edema and ecchymosis. *Aesthetic Plast Surg.* 2018;42(1):246-52. [Crossref] [PubMed]
- Totonchi A, Guyuron B. A randomized, controlled comparison between arnica and steroids in the management of post-rhinoplasty ecchymosis and edema. *Plast Reconstr Surg.* 2007;120(1):271-4. [Crossref] [PubMed]
- Gurlek A, Fariz A, Aydogan H, Ersoz-Ozturk A, Eren AT. Effects of different corticosteroids on edema and ecchymosis in open rhinoplasty. *Aesthetic Plast Surg.* 2006;30(2):150-4. [Crossref] [PubMed]
- Kargi E, Hoşnüter M, Babuççu O, Altunkaya H, Altinyazar C. Effect of steroids on edema, ecchymosis, and intraoperative bleeding in rhinoplasty. *Ann Plast Surg.* 2003;51(6):570-4. [Crossref] [PubMed]

35. Hwang SH, Lee JH, Kim BG, Kim SW, Kang JM. The efficacy of steroids for edema and ecchymosis after rhinoplasty: a meta-analysis. *Laryngoscope*. 2015;125(1):92-8. [[Crossref](#)] [[PubMed](#)]
36. Gun R, Yorgancılar E, Yıldırım M, Bakır S, Topcu I, Akkus Z. Effects of lidocaine and adrenaline combination on postoperative edema and ecchymosis in rhinoplasty. *Int J Oral Maxillofac Surg*. 2011;40(7):722-9. [[Crossref](#)] [[PubMed](#)]
37. Chaiet SR, Marcus BC. Perioperative arnica montana for reduction of ecchymosis in rhinoplasty surgery. *Ann Plast Surg*. 2016;76(5):477-82. [[Crossref](#)] [[PubMed](#)]
38. Kara CO, Kara IG, Topuz B. Does creating a subperiosteal tunnel influence the periorbital edema and ecchymosis in rhinoplasty? *J Oral Maxillofac Surg*. 2005;63(8):1088-90. [[Crossref](#)] [[PubMed](#)]
39. Sakallıoğlu Ö, Cingi C, Polat C, Soylu E, Akyigit A, Soken H. Open versus closed septorhinoplasty approaches for postoperative edema and ecchymosis. *J Craniofac Surg*. 2015;26(4):1334-7. [[Crossref](#)] [[PubMed](#)]
40. Kelleş M, Erdem T, Fırat Y, Kalcıoğlu MT, Akarçay M, Selimoğlu E, et al. [Efficacy of local heparinoids on preventing edema and ecchymosis after rhinoplasty]. *Kulak Burun Bogaz İhtis Derg*. 2010;20(4):191-4. Turkish. [[PubMed](#)]
41. Knackstedt R, Gatherwright J. Perioperative homeopathic arnica and bromelain: current results and future directions. *Ann Plast Surg*. 2020;84(3):e10-e15. [[Crossref](#)] [[PubMed](#)]