

# Pyogenic Granuloma of the Middle Turbinate: A Rare Location

## Orta Konkanın Piyojenik Granülomu: Nadir Bir Yerleşim Yeri

Bahtiyar HAMİT, MD,<sup>1</sup> Suat BİLİCİ, MD,<sup>1</sup> Özgür YİĞİT, MD,<sup>1</sup> Erol Rüştü BOZKURT, MD<sup>2</sup>

<sup>1</sup> İstanbul Training and Research Hospital, Clinic of Otorhinolaryngology,

<sup>2</sup> İstanbul Training and Research Hospital, Clinic of Pathology, İstanbul

---

### ABSTRACT

---

Pyogenic granuloma is a benign, hyperplastic vascular lesion that occurs rarely in the nose. The etiology is uncertain; it frequently occurs following traumatic and hormonal changes, particularly in pregnancy. We report a case of 34-year-old female with a unilateral pyogenic granuloma of the middle turbinate, who presented with nasal obstruction and epistaxis. We emphasize that the rarely seen pyogenic granuloma must be kept in mind in the differential diagnosis of a rapidly growing mass of the nasal cavity, especially after a pregnancy period.

#### Keywords

*Granuloma, pyogenic, nasal obstruction, epistaxis*

---

### ÖZET

---

Piyojenik granülom burun içinde nadir görülen selim, hiperplastik vasküler bir lezyondur. Etyolojisi tam olarak bilinmemekle beraber, özellikle hamilelikteki hormonal değişikliklerle ve travmatik nedenlerle sıklıkla ortaya çıkmaktadır. Bu yazımızda, burun tıkanıklığı ve burun kanaması yakınması olan 34 yaşındaki bayan hastada orta konkanın tek taraflı piyojenik granülom olgusunu sunduk. Özellikle hamilelik sonrasında burun içinde hızla büyüyen kitlelerin ayırıcı tanısında nadir görülen piyojenik granülomanın akılda tutulması gerektiğini vurguladık.

#### Anahtar Sözcükler

*Granülom, piyojenik, nazal tıkanıklık, burun kanaması*

**This paper was presented as poster at 11<sup>th</sup> Turkish Rhinology Congress 16-19 April 2015, Antalya.**

Çalışmanın Dergiye Ulaştığı Tarih: **20.07.2015**

Çalışmanın Basıma Kabul Edildiği Tarih: **15.12.2015**



Correspondence

**Bahtiyar HAMİT, MD**

İstanbul Training and Research Hospital,

Clinic of Otorhinolaryngology, İstanbul

E-mail: bahtiyar\_864@hotmail.com

## INTRODUCTION

Pyogenic granuloma (PG) is a benign vascular lesion with an exact pathogenesis that continues to be debated.<sup>1</sup> The major causes of pyogenic granulomas have been suggested to include nasal injury or hormonal changes.<sup>2</sup> Postoperative nasal packing and intraoperative trauma are known as the most common causes resulting in nasal injury.<sup>2-4</sup> Pyogenic granuloma commonly occurs in the head and neck region, but its occurrence in the nasal cavity is a relatively rare location. The anterior part of septum is the most frequently affected region in the nasal cavity. The incidence of PG is greatest in females and in the third decade. The incidence has been reported to be approximately 5% higher during pregnancy.<sup>5</sup> In addition, it has been known to resolve spontaneously after a pregnancy period.<sup>6</sup>

The middle turbinate is a very rare site for the occurrence of pyogenic granuloma. To contribute to the literature, we present a case of a patient with a pyogenic granuloma located on the middle turbinate, who presented with nasal obstruction and epistaxis.

## CASE REPORT

A 34-year-old woman was referred to the department of otorhinolaryngology with a four-month history of nasal obstruction and intermittent nasal bleeding on the right side. Nasal endoscopy revealed a fragile, partly sloping, reddish-pink mass arising from the right middle turbinate. Her otolaryngologic examination was otherwise normal. She had no history of trauma or nasal packing. Axial computed tomography (CT) of the paranasal sinus showed a soft tissue mass arising from the right middle turbinate (Figure 1). There was no evidence of bony erosion. The size of the mass was approximately 12\*10\*8 mm. A punch biopsy of the nasal mass was done under local anaesthesia. The pathology result was pyogenic granuloma. Preoperative laboratory testing was normal and surgery was done under general anaesthesia. Using a 30° nasal telescope, the mass was excised, together with the inferior 1/3<sup>rd</sup> of the middle turbinate, via nasal forceps and suction cautery (Figure 2). Minimal bleeding was controlled via bipolar electrocautery. The postoperative period was uneventful and the patient had no complaints. Histopathological examination of the nasal mass revealed it to be a pyogenic granuloma. At the 1-year postoperative follow-up, there was no evidence of recurrence or residual disease.

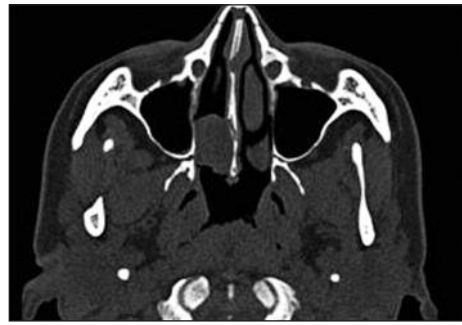

Figure 1. Axial CT of paranasal sinus shows the soft tissue mass originating from the right middle turbinate.

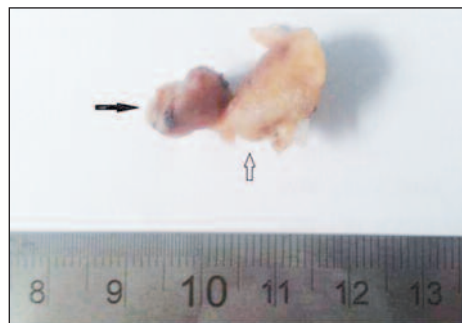


Figure 2. Postoperative surgical specimen. Black arrow is PG, white arrow is 1/3<sup>rd</sup> inferior part of middle turbinate.

## DISCUSSION

Although pyogenic granuloma is also known as lobular capillary haemangioma, the term “pyogenic granuloma” is commonly used in literature.

Pyogenic granuloma especially occurs in the oral cavity in the head and neck region, commonly on the gingiva; however, it is unusual to find it in the nasal cavity. Patrice et al, in a large series of 178 cases, declared that the head and neck regions, and especially the oral cavity, were the most common sites for occurrence of PG (62.4%).<sup>4</sup> Within the nasal cavity, PGs particularly occur in the anterior nasal septum and less frequently in the inferior turbinate.<sup>7</sup> The middle turbinate region is a very rare site for PG. In the patient reported here, the lesion originated from the lateral aspect of the middle turbinate and filled the middle meatus, proceeding as far as the inferior turbinate as a reddish-pink polypoid mass, which caused no destruction to the surrounding soft tissue.

The pathogenesis of pyogenic granuloma is still unclear. Trauma is accepted as a major cause of PG. However, history of nasal trauma was only 7% in a series by Patrice et al.<sup>8</sup> Trauma induced by nasal packing

is very often a cause of PG. Some publications have reported PG as a complication of nasal packing.<sup>9-12</sup> Pyogenic granuloma can also occur in association with hormonal changes, as seen during pregnancy period.<sup>13</sup> Development of PG in our case could not have been trauma induced by nasal packing, but our patient had a history of pregnancy one year previously.

Although pyogenic granuloma occurs at all ages, it most frequently is seen in the third decade and is more common in females. In the paediatric age group, PG frequently occurs in males.<sup>14</sup>

The most frequent presenting symptom associated with nasal PG is unilateral epistaxis. Nasal obstruction, rhinorrhoea, facial pain, headache, hyposmia and epiphora are less common symptoms.<sup>5</sup> In our case, the major symptom was nasal obstruction and the intermittent epistaxis was another symptom. Pyogenic granuloma frequently presents as a red-pink coloured mass, lobulated, wide-based or pedunculated; usually smooth-surfaced, and may become ulcerated due to exposure to trauma, with variation in size. It is often not painful and non-tender on manipulation.<sup>1</sup>

A wide range of different pathologies can imitate PG. Hence, in the differential diagnosis of intranasal PG, Wegener's granulomatosis, haemangiosarcomas, angiosarcomas, Kaposi's sarcomas, nasal polyp, sarcoidosis, simple granulation tissue, papilloma, squamous cell carcinoma, mucosal malignant melanoma and lymphoma should be considered.<sup>1,11</sup>

Histopathologically, the lesion is characterized by varying-sized capillaries in a lobular arrangement, often surrounded by a central calibre vessel.<sup>12</sup> Pseudostratified, ciliated epithelium cover the entire lesion and some parts can be eroded. In our case, the surface

of the mass was partly covered by epithelium of the upper respiratory tract and the lesion included lobulated vascular areas. Higher magnification revealed many vascular structures with thin walls under the ulcerated mucosa. In addition, mononuclear inflammatory cells were noted on histological examination (Figure 3a, b).

PG is a non-neoplastic lesion and may resolve spontaneously. The treatment is surgical extirpation and recurrences are uncommon. Endoscopic surgery provides wonderful visualization of the lesion and surrounding anatomy, and also allows optimal control of bleeding<sup>5</sup>. In adult patients with small anterior lesions, surgery is preferred under local anaesthesia. In the case report herein, we preferred total excision of mass, together with the inferior 1/3<sup>rd</sup> of the middle turbinate, via endoscopic surgery under general anaesthesia. The mass was removed easily without significant bleeding.

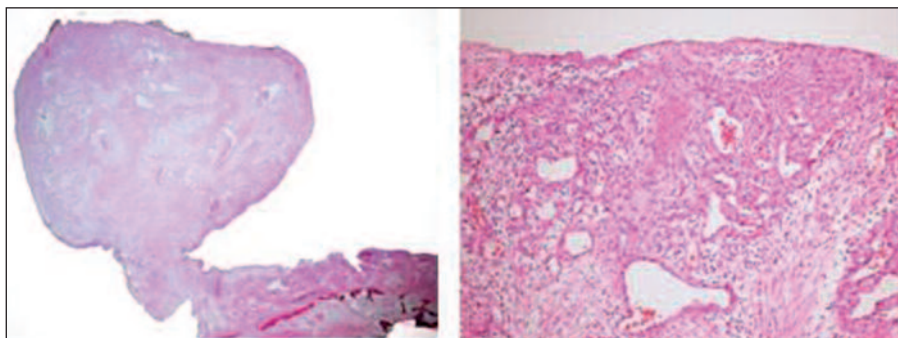
Alternatively to the surgical treatment, Noubom et al. reported the likelihood of treatment of PG with the combination of rifampicin and dapsone for a duration of one month.<sup>15</sup> Their dosage, and interaction with each other in the treatment of pyogenic granuloma, needs further evaluation.

---

## CONCLUSION

---

We reported a rare case of middle turbinate PG in an adult female after a pregnancy period. We advocate that PG should be considered, in patients with nasal obstruction and epistaxis, in the differential diagnosis of any middle turbinate mass. Though recurrence is rare, follow-up must be attentive.



**Figure 3.** Histology showing vascular areas of lobulated, thin walled vascular structures and mononuclear inflammatory cells (HE) in 40x and 100 x respectively.

## REFERENCES

1. Kumar RA, Babu MM, Venkatarajamma PR, Mishra U. Pyogenic granuloma of nasal septum: A case report and review of literature. *Int J Otolaryngol Head Neck Surg* 2014;3(4):190-4.
2. Lee JH. A case of postoperative pyogenic granuloma at the middle turbinate. *J Rhinol* 2009;16(1):58-60.
3. Katori H, Tsukuda M. Lobular capillary hemangioma of the nasal cavity in child. *Auris Nasus Larynx*. 2005;32(2):185-8.
4. Patrice SJ, Wiss K, Mulliken JB. Pyogenic granuloma (lobular capillary hemangioma): a clinicopathologic study of 178 cases. *Pediatr Dermatol*. 1991;8(4):267-76.
5. Puxeddu R, Berlucchi M, Ledda GP, Parodo G, Farina D, Nicolai P. Lobular capillary hemangioma of the nasal cavity: A retrospective study on 40 patients. *Am J Rhinol* 2006; 20(4):480-4.
6. Hassan NE, Goh BS. Pyogenic granuloma of the nasal septum: A rare cause of epistaxis. *Brunei Int Med J* 2012;8(6):367-70.
7. El-Sayed Y, Al-Serhani A. Lobular capillary hemangioma (pyogenic granuloma) of the nose. *J Laryngol Otol* 1997;111(10):941-5.
8. Requena L, Sanguenza OP. Cutaneous vascular proliferation. Part II. Hyperplasias and benign neoplasms. *J Am Acad Dermatol*. 1997;37(6):887-919.
9. Bhattacharyya N, Wenokur RK, Goodman ML. Endoscopic excision of a giant pyogenic granuloma of the nasal cavity caused by nasal packing. *Rhinology* 1997;35(1):44-5.
10. Sheen TS, Ko JY, Hsu YH. Pyogenic granuloma-an uncommon complication of nasal packing. *Am J Rhinol* 1997;11(3):225-7.
11. Lee HM, Lee SH, Hwang SJ. A giant pyogenic granuloma in the nasal cavity caused by nasal packing. *Eur Arch Otorhinolaryngol* 2002;259(5):231-3.
12. Kurtaran H, Uraldi C, Ark N, Aktaş D. Lobular capillary hemangioma of the middle turbinate. *Acta Otolaryngol* 2006;126(4):442-4.
13. Delbrouck C, Chamiec M, Hassid S, Ghanooni R. Lobular capillary hemangioma of the nasal cavity during pregnancy. *J Laryngol Otol* 2011;125(9):973-7.
14. Mills SE, Cooper PH, Fechner RE. Lobular capillary hemangioma: the underlying lesion of pyogenic granuloma. A study of 73 cases from the oral and nasal mucous membranes. *Am J Surg Pathol*. 1980;4(5):470-9.
15. Noubom M, Kenfack B, Donfack JH, Nembot FD, Sando Z. Clinical case of botryomycosis fulminant at the center of diagnostic and treatment of tuberculosis of Baleng (West - Cameroon). *Pan Afr Med J*. 2013;4(14):131.